

LuxaCrown Case Reports

A series of case reports showing clinical challenges and their treatment solution with LuxaCrown, a new semi-permanent restoration material.

I.	Fabrication of semi-permanent restorations using LuxaCrown. <i>Dr. Chu Thi Quynh Huong, Vietnam</i>	4-5
II.	An easy, quick and cost-effective way for semi-permanent restorations. LuxaCrown. <i>Dr. Chu Thi Quynh Huong, Vietnam</i>	6-7
III.	Modern semi-permanent restoration in practice. <i>Prof. Dr. Elmar Reich, Germany</i>	8-9
IV.	Direct composite crown with LuxaCrown. <i>Dr. Daniel Farhan MSc., Germany</i>	10-11
V.	LuxaCrown for provision of a front tooth gap with a semi-permanent restoration. <i>Dr. Gerd Göstemeyer, Germany</i>	12-14
VI.	Semi-permanent restoration – a preview of definitive treatment. <i>Dr. Mirko Christian, Dentist Christian Grünler, Dentist Linda Wolf, Germany</i>	15-17
VII.	Semi-permanent restoration – functional and esthetic success. <i>Dr. Mirko Christian, Dentist Christian Grünler, Dentist Linda Wolf, Germany</i>	18-19
VIII.	Semi-permanent fixed dental prostheses to optimize the treatment result. <i>Dentist Lars Ahlskog, Dr. Katharina Kuhn, Germany</i>	20-22
IX.	Cost effective, esthetic, long term temporary crowns. <i>Prof. Dr. Neeraj Gugnani, India</i>	23-27
X.	Restoring aesthetics and function with a reliable long-term restoration. Application of a new semi-permanent material for exceptional clinical results. <i>Dr. Kleanthis Manolakis, DDS, Anthi Batziou, DDS, Greece</i>	28-30

Fabrication of semi-permanent restorations using LuxaCrown.

Dr. Chu Thi Quynh Huong, Vietnam

DIAGNOSIS

A 73 year old female patient with esthetic and functional problems applied to the clinic. The patient had a removable partial denture and multiple old class V restorations. Due to staining she was not satisfied with her smile. In addition to that adhesion failure of some direct restorations caused an instability of her removable partial denture.

In order to achieve a sufficient stability of the denture and to improve the esthetic outcome, two semi-permanent restorations were planned for the right first and second mandible pre-molar using the semi-permanent material LuxaCrown by DMG.

TREATMENT

The Patient underwent a comprehensive clinical examination which was completed with preliminary photographs (Figs. 1-2). A direct mock-up was placed onto the teeth in order to get an ideal anatomic form (Fig. 3). This mock-up simulated the shape of the final restoration. From this situation an impression was taken.

Afterwards the two teeth were prepared (Fig. 4). LuxaCrown was applied into the situation impression and the impression was replaced over the prepared teeth. After 90 seconds the impression was removed from the mouth and the LuxaCrown restorations were removed from the impression. At the end of the setting time of the material the restorations were shaped, contoured and polished with a composite polishing instrument.

After checking the marginal fit, the prepared teeth were thoroughly cleaned and dried.

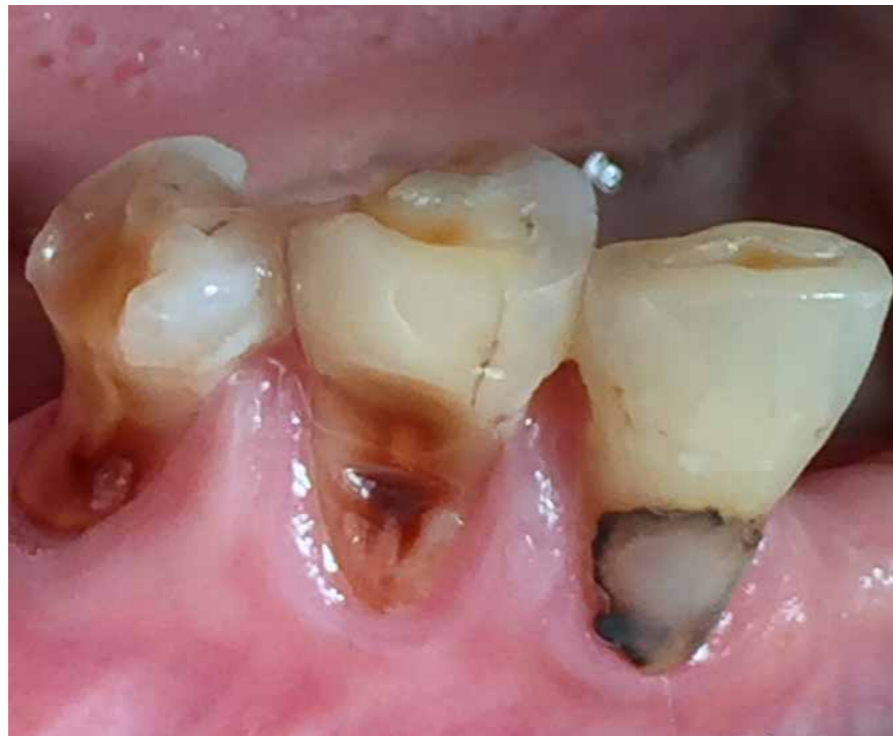

Fig. 2: Compromised teeth.

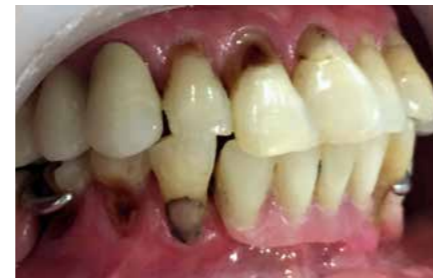

Fig 1: Intraoral initial situation with removable partial denture in situ.

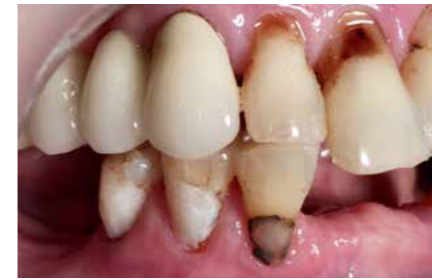

Fig. 3: Intraoral situation with direct mock-up.

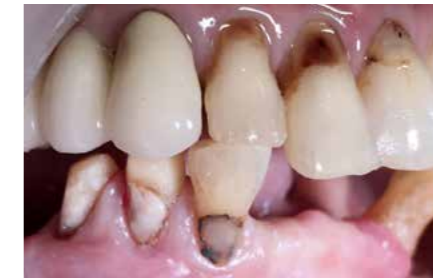

Fig. 4: Prepared teeth.

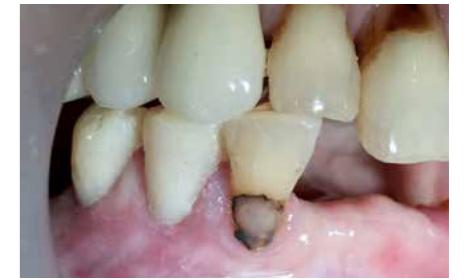

Fig. 5: Cemented LuxaCrown restorations.

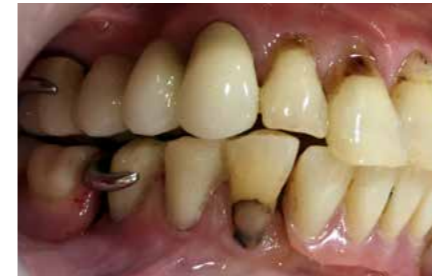

Fig. 6: Checking the occlusion.

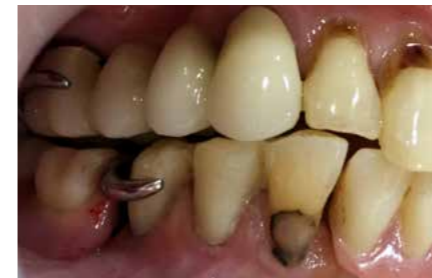

Fig. 7: Final situation with LuxaCrown.

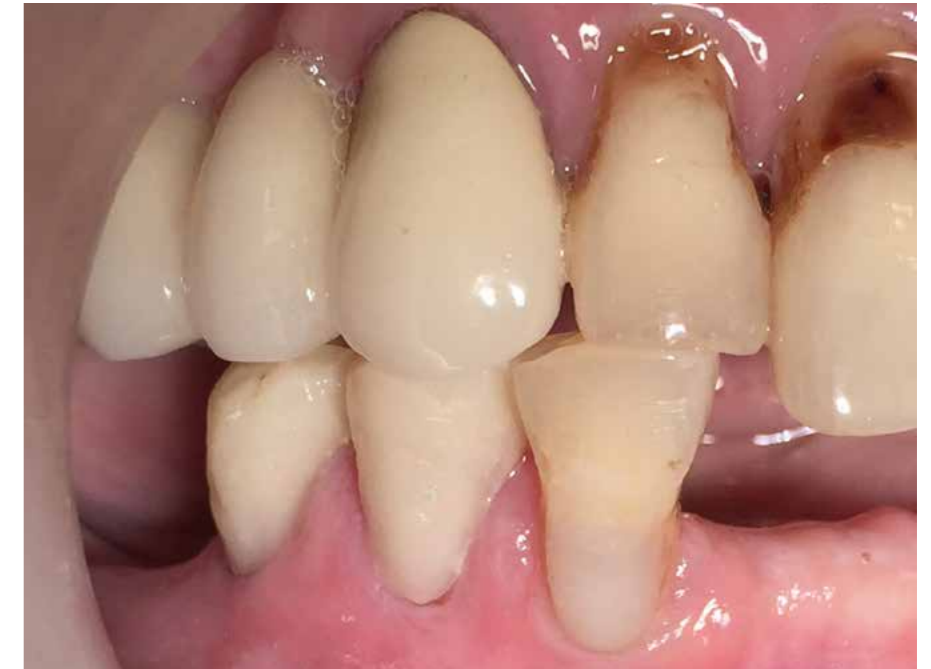

Fig. 8: Intraoral situation without removable partial denture in situ 2 weeks after treatment. The vestibular filling at the lower canine next to the restored teeth had also been replaced.

Then the restorations were cemented and the occlusion was adjusted (Figs. 5-8).

CONCLUSION

Tooth retained removable partial dentures often lead to increased stress on the abutment teeth. Especially when class V restorations are involved, the stress can result in adhesion failure followed by a compromised stability of the partial denture. In this case the application of LuxaCrown for the fabrication of semi-permanent crowns offered the possibility to improve the stability and retention of the removable partial denture.

Furthermore the restorations improved the esthetic situation.

In conclusion, LuxaCrown offers an easy, quick and cost-effective way to fabricate semi-permanent restorations with excellent marginal fit and stability.

CONTACT

Dr. Chu Thi Quynh Huong
Trung Tu, Nhà E4, 1 Tôn Thất Tùng, Trung Tu,
Đống Đa, Hanoi, Vietnam

An easy, quick and cost-effective way for semi-permanent restorations. LuxaCrown.

Dr. Chu Thi Quynh Huong, Vietnam

DIAGNOSIS

A 65 year old female patient approached the clinic for restorations of lower anterior teeth. She complained about the unesthetic appearance of her lower teeth and hypersensitivity to hot and cold food. At her lower anterior teeth 31 and 32, there were insufficient direct composite restorations with secondary caries and a compromised anatomic form due to attrition. The antagonists are restored with porcelain crowns.

In order to restore the caries lesions and to improve the anatomic form, two semi-permanent restorations were planned for teeth 31 and 32 using LuxaCrown by DMG.

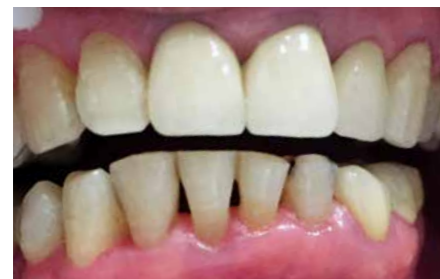

Fig. 1: Intraoral initial situation.

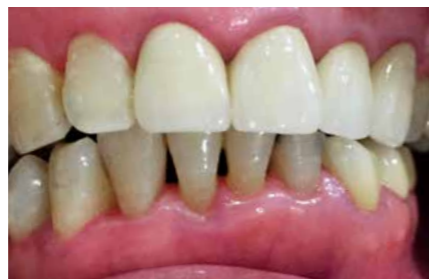

Fig. 2: Intraoral Pretreatment.

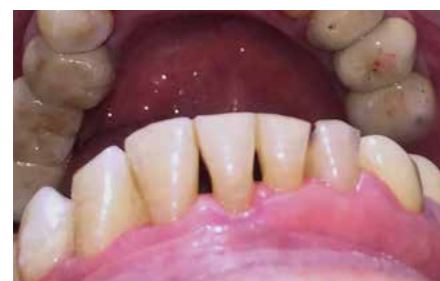

Fig. 3: Intraoral Pretreatment.

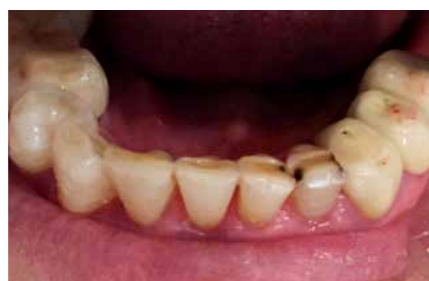

Fig. 4: Intraoral Pretreatment.

TREATMENT

The Patient underwent a comprehensive clinical examination which was completed with preliminary photographs (Figs.1-4).

A direct mock-up was placed onto the teeth in order to get an ideal anatomic form (Fig. 5). This mock-up simulated the shape of the final restoration. From this situation an impression was taken.

Afterwards the two teeth were prepared (Figs. 6 and 7). LuxaCrown was applied into the situation impression and the impression was replaced over the prepared teeth. After 90 seconds, the impression was removed from the mouth and the LuxaCrown restorations were removed from the impression.

At the end of the setting time of the material the restorations were shaped, contoured and polished with a composite polishing instrument.

After checking the marginal fit the prepared teeth were thoroughly cleaned and dried. Then the restorations were cemented and the occlusion was adjusted (Figs. 8-11).

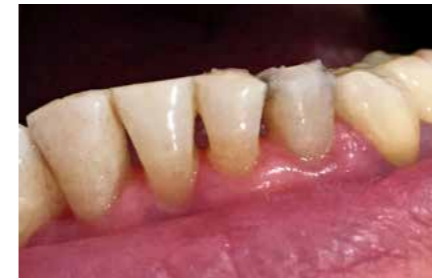

Fig. 5: Intraoral situation with direct mock-up.

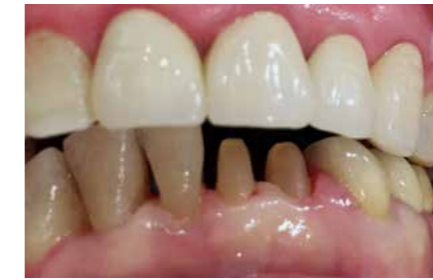

Fig. 6: Prepared teeth.

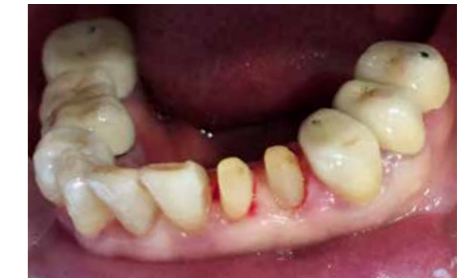

Fig. 7: Prepared teeth.

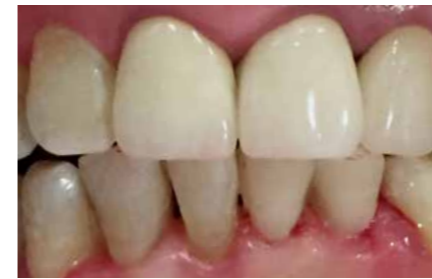

Fig. 8: Cemented LuxaCrown restorations.

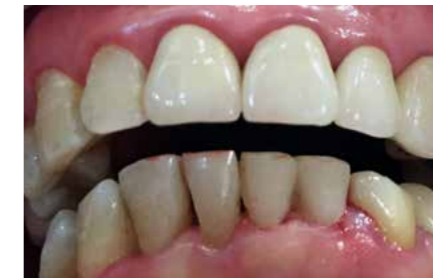

Fig. 9: Checking the occlusion.

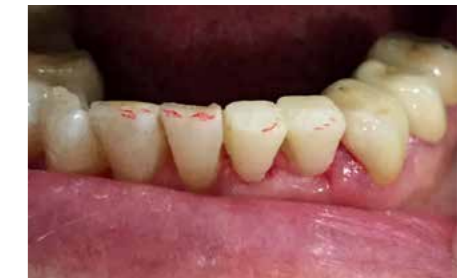

Fig. 10: Checking the occlusion.

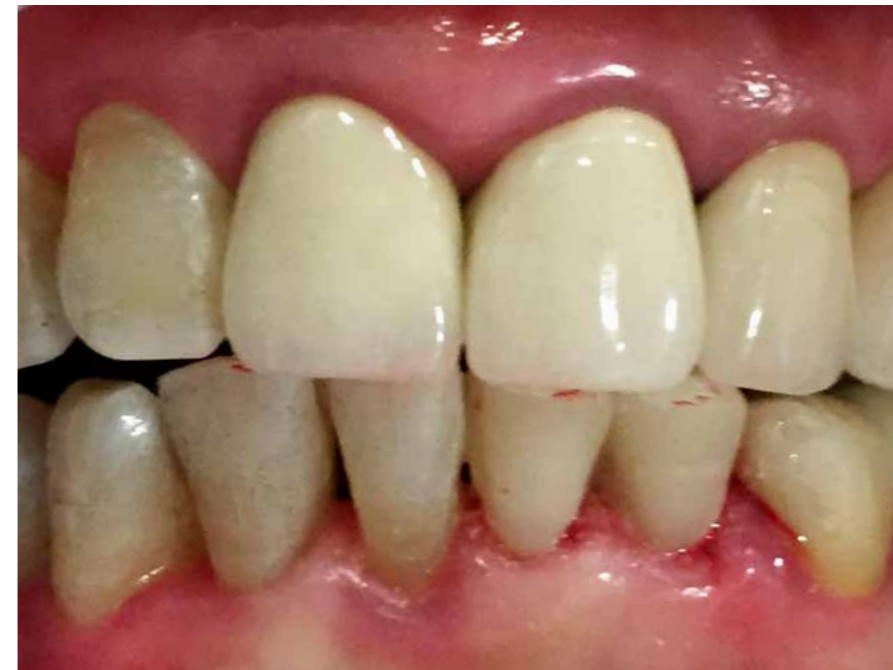

Fig. 11: Checking the occlusion.

CONCLUSION

Restoring the lower anterior teeth 31 and 32 with the semi-permanent material LuxaCrown led to esthetic and functional improvement of the clinical situation. LuxaCrown offers an easy, quick and cost-effective way to fabricate semi-permanent restorations with excellent marginal fit and stability.

CONTACT

Dr. Chu Thi Quynh Huong
 Trung Tu, Nhà E4, 1 Tôn Thất Tùng
 Trung Tu, Đống Đa, Hanoi
 Vietnam

Modern semi-permanent restoration in practice.

Prof. Dr. Elmar Reich, Germany

In current preparation techniques and modern ceramics, dentists are confronted with a problem when it comes to the high demands placed on temporary materials today. Many of these materials cannot withstand stresses while chewing for very long, or the connection with the temporary cement quickly comes loose again. This leads, in practice, to awkward reconstructions and pain and frustration on the part of the patient. In practice, the production of semi-permanent restorations is always a critical process because, at times, the associated patient requirements are very high and direct construction in the mouth brings with it some problems. For in-mouth construction we use either a silicone impression or a vacuum-formed template of the model. Right after the preparation, there is blood and saliva on the stump that must be removed before applying the plastic material. Composite structures sometimes become attached to the material, but can be isolated. In many temporary composite materials blistering and defects occur on the margin of the temporary restoration because the materials are relatively viscous, making awkward reworking necessary.

Any modern temporary material must show in clinical use how it withstands the esthetic demands of the patient and the technical requirements, as well as clinical stresses. DMG LuxaCrown can, like all current

temporary materials, be worked directly in the mouth without issue. It flows very thinly in the process so that even fine margins are well molded.

An implant was necessary in the young patient following a fracture of tooth 21. During the healing phase of the implant a composite bridge was created directly in-mouth over implant 21 between the natural neighboring teeth (Fig. 1). It was discovered during the try-in of the zirconium abutment on the titanium implant (Fig. 2) that the shade and shape of the implant crown needed to be adapted in the lab. For that reason a decision

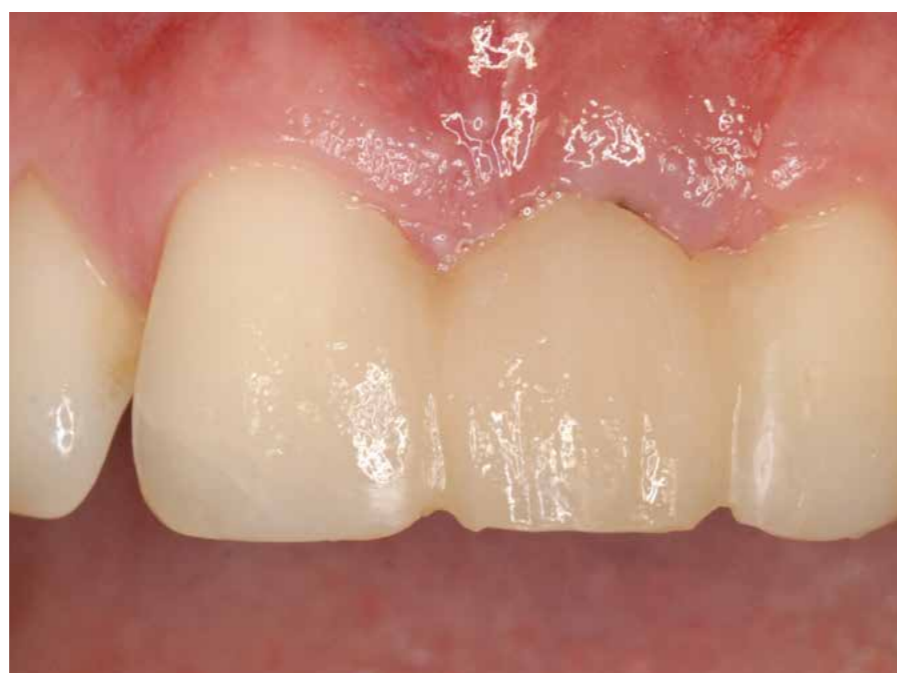

Fig. 1: Composite bridge over implant 21.

was made to give the implant a semi-permanent restoration with a regio 21 zirconium abutment.

A semi-permanent crown (Fig. 3) was created in-mouth with the aid of a silicone impression of the implant crown using DMG LuxaCrown. The material is low-viscosity, but firm, meaning that in-mouth repositioning of the silicone impression with the semi-permanent material does not pose any difficulty (Fig. 4). The material flows onto the stump easily and should cure in the mouth for approx. 2 minutes. After removal from the mouth, the little excess material can be easily removed

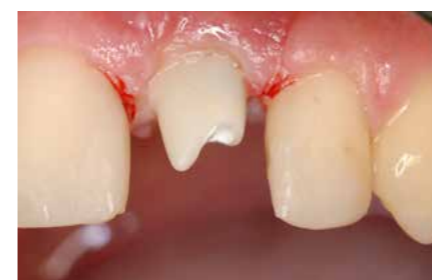

Fig. 2: Zirconium abutment on a regio 21 implant.

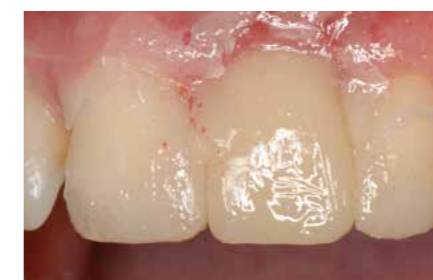

Fig. 3: Creation of a direct restoration with DMG LuxaCrown.

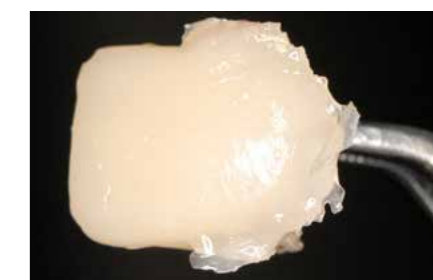

Fig. 4: Restoration with excess material before finishing.

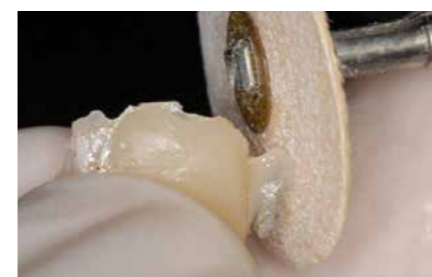

Fig. 5: Removal of the excess with polishing wheel.

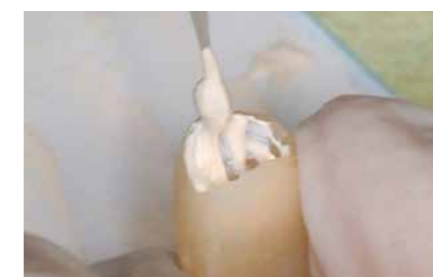

Fig. 6: Try-in of restoration on the implant abutment.

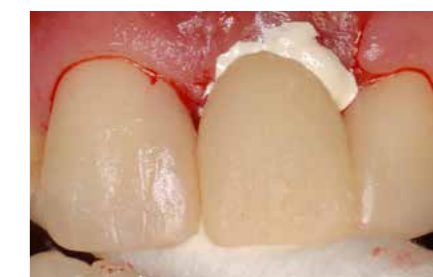

Fig. 7: Insertion of the restoration with TempBond while patient bites down lightly on cotton wool roll.

with a polishing wheel (Fig. 5) or a diamond bur. After trying the restoration in the mouth and adjusting the occlusion, the shade and shape were found to be a good match with the natural teeth. The shape and contact with the neighboring teeth are fine and, following a brief polish on the chair with a fine diamond bur and some silicone polishing, the restoration is ready for use.

The luting to the zirconium abutment was done, as usual, using TempBond, with a cotton wool roll used to hold in place (Figs. 6 and 7). The restoration is very stable and the cement will not come off as easily as with softer materials. After a few days in the mouth no discoloration was identifiable (Fig. 8).

The low layer thickness of the material is orally recognizable. Nonetheless, the restoration remains very stable and had not come loose. The properties of the DMG LuxaCrown material are very good and make clinical work much easier. Thanks to its robustness, restorations are able to effectively withstand chewing stresses and occlusal relationships remain stable.

One thing which is very positive about this material in clinical use is its stability even with thin margins in the frontal and posterior tooth area. In the posterior tooth area too, e.g. in the case of temporary restorations for ceramic partial crowns, patients were able to chew

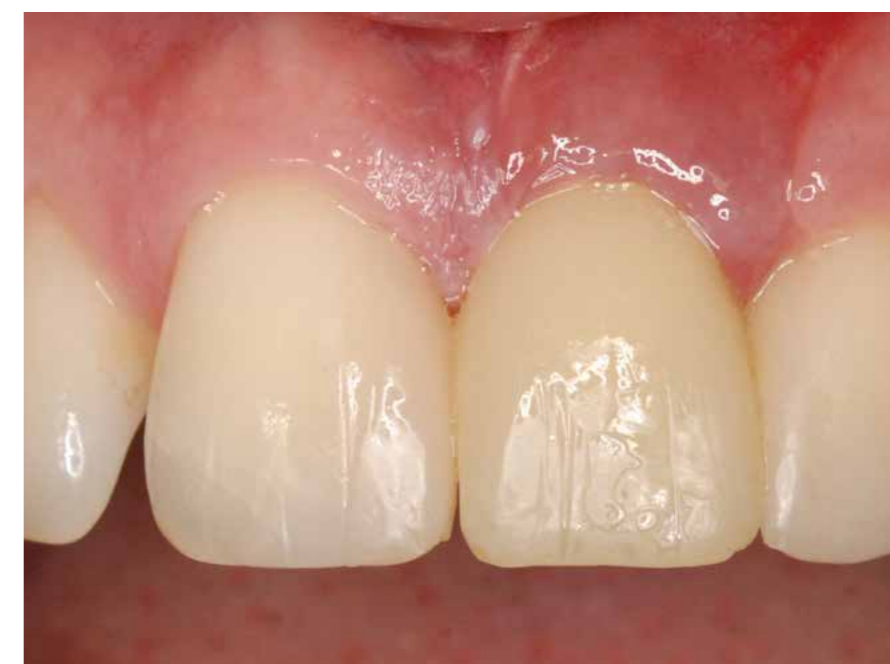

Fig. 8: Restoration after a few days in mouth.

effectively and these remained securely in place with TempBond.

The DMG LuxaCrown material can be finished easily and quickly at the chair. Thin margins can be finished with fine diamond burs and polishing with a silicone polisher produces a smooth temporary restoration surface which is pleasant for patients.

CONTACT

Prof. Dr. Elmar Reich
Dental Practice ZAHNprofILAXE
Rolf-Keller-Platz 1
D-88400 Biberach
Germany

Direct composite crown with LuxaCrown.

Dr. Daniel Farhan MSc., Germany

Indirect restorations are used regularly in prosthetic dentistry and can be differentiated in various classes. Areas in which they differ include the retention period in the mouth.

On the one hand, there are temporary measures worn for a short period of time which are used to protect the ground tooth until the final dental prosthesis is inserted and, on the other, there are long-term temporaries, often used in the treatment of teeth which might be at risk.

These are either used only to guarantee the prognosis of the tooth to be given a crown for a certain period, often 3-6 months, or also, in cases where a risky situation is essentially undergoing "final" restoration.

Thus, figuratively speaking, these assume the same functions as a final dental prosthesis, which increases the demands placed on the materials used when it comes to marginal seal, resilience and long-term stability. This gives rise to the question of whether long-term temporaries can remain in the mouth for an unlimited period in special indication groups.

MATERIAL:

A clinical example is used to illustrate the use of the novel new crown composite (LuxaCrown) for the fabrication of a long-

term temporary with as-yet undefined end of wear. The materials used (StatusBlue, LuxaCrown, Luxatemp-Glaze & Bond) are manufactured by the company DMG (DMG, Hamburg).

CLINICAL CASE:

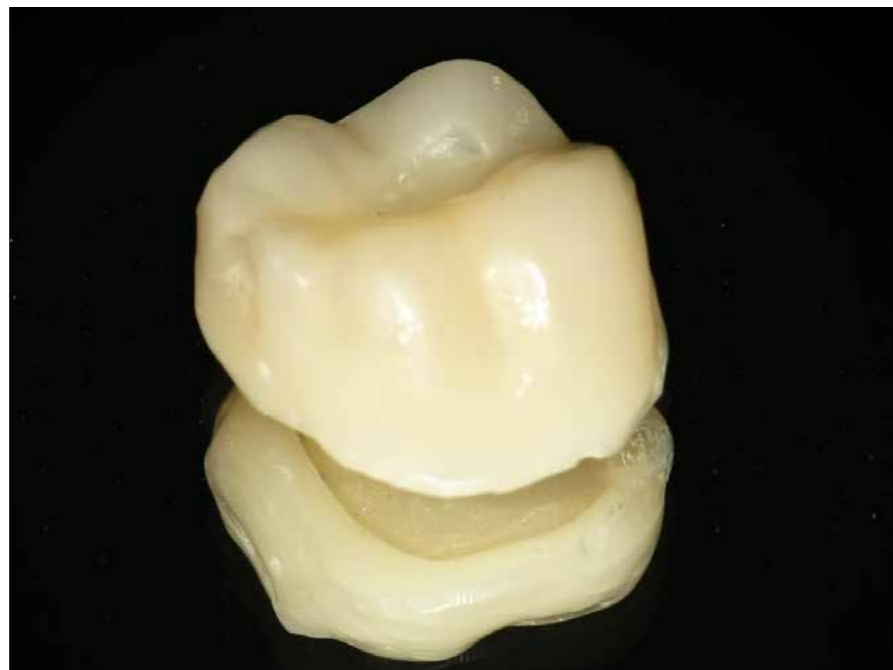A 63-year old male patient presented himself at our dental practice with significant pain in tooth 46.

Following findings and diagnosis, the tooth received endodontic treatment. In this

specific case, we decided to remove the existing crown following a corresponding pre-impression with the A-silicon StatusBlue (DMG), so as to allow as germ-free an endodontic treatment as possible (Figs. 1 and 2).

This was to prevent any compromise on the subsequent endodontic result due to an insufficient margin fit and any resulting coronal leakage.

The plans for the prosthetic restoration included a customized semi-permanent chair side restoration in a direct procedure using



Final LuxaCrown restoration on a mirror.

the innovative crown material LuxaCrown. This material makes it possible to restore the tooth for the long-term without compromising on the margin fit, resilience, shade stability or esthetic reconstruction.

Following successful root canal treatment, the severely damaged tooth stump was reconstructed using an adhesive post abutment (LuxaPost and LuxaCore Z, both from DMG) before undergoing the standard preparation for the incorporation of a single crown (Figs. 3 and 4).

After checking for undercut areas the stump was lightly isolated with Vaseline.

The impression produced with StatusBlue was then filled with LuxaCrown (Figs. 4 and 5) and the tray was repositioned in the patient's mouth 30 s afterwards at the latest. During the elastic phase of the crown material, which spans a period between 1:30 and 2:20 minutes, the impression must be removed. The semi-permanent restoration achieved the final hardness after 5 minutes.

After removing the crown from the impression (Fig. 6), the rough excess was removed with crown shears and the crown was placed on the stump to check the fit. Afterwards, final finishing was done extra-orally using mills and rubber polishers as well as polishing brushes (Figs. 7 and 8). Then the crown was cemented with Ketac Cem according to manufacturer instructions.

The intra-oral result was more than satisfactory as far as the fit and esthetics were concerned (Figs. 9-10).

CONTACT

Dr. Daniel Farhan MSc.
Kurfürstenanlage 7
69115 Heidelberg
Germany

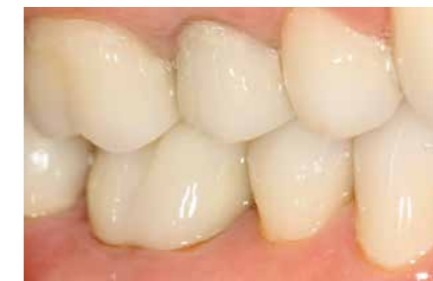

Fig. 1: Initial situation, side view.

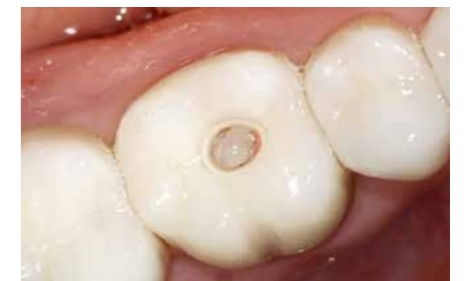

Fig. 2: Interoral initial situation, occlusal.

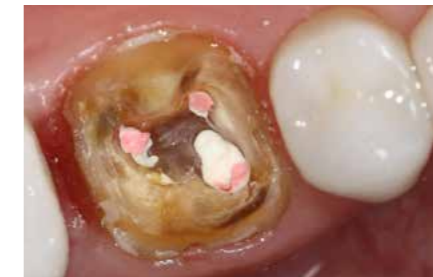

Fig. 3: After root canal treatment.

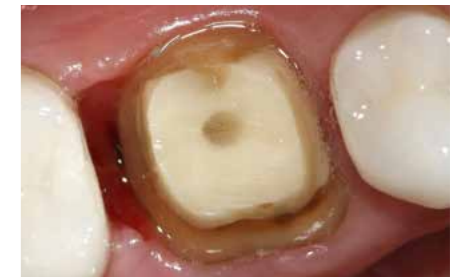

Fig. 4: After root canal treatment.

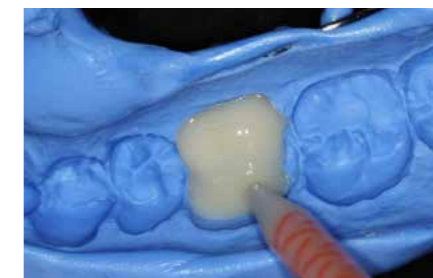

Fig. 5: Filling impression with LuxaCrown.

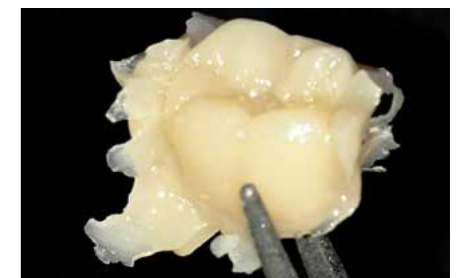

Fig. 6: Removing LuxaCrown from impression.

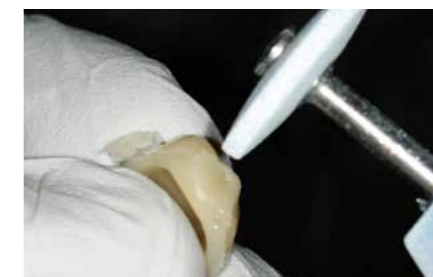

Fig. 7: Final polishing with rubber polisher.

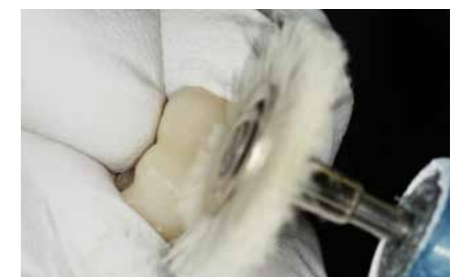

Fig. 8: Final polishing.

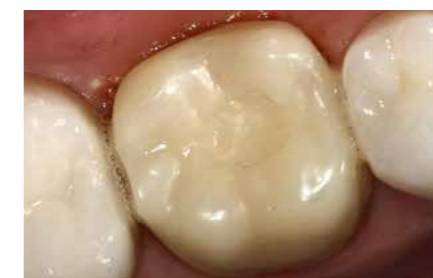

Fig. 9: LuxaCrown interoral, view occlusal.

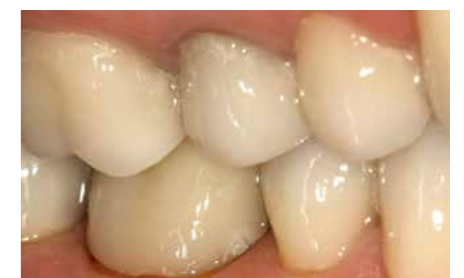

Fig. 10: LuxaCrown, side view.

LuxaCrown for treatment of an anterior tooth gap with a semi-permanent restoration.

Dr. Gerd Göstemeyer, Germany

In everyday practice, situations arise in which dental prostheses need to be produced at relatively short notice. Particularly where teeth need to be extracted and at first, until the final restoration can be inserted, bone regeneration should have occurred, it is advantageous if the temporary restoration created has good durability. LuxaCrown is a readily available highly-durable semi-permanent composite material with which it is possible to manufacture, with the simple means available in the dental practice, crowns and bridges which are suitable for long-term temporary measures.

CLINICAL CASE

The 54-year-old patient visited our clinic because she noticed a tooth mobility as well as a “bad taste” on tooth 11. The clinical examination revealed that the gingiva on tooth 11 and 12 was reddened and swollen (Figs. 1 and 2). It was found that the splinted crowns on these teeth had a mobility of grade II. A circular probing depth of up to 10 mm was measured on tooth 11 (Fig. 3). The x-ray image taken showed a pronounced periodontic-endodontic lesion on tooth 11 (Fig. 4). The root shortened by a root end surgery carried out alio loco was no longer connected to the alveolar bone. Tooth 11 was therefore classed as not worth preserving. Given the risk of luxation of tooth 12 due to the interlocking with tooth 11 there was an urgent need for treatment. We discussed with the patient the possible alternatives to a temporary replacement of tooth 11 after extraction (e.g. insertion of a lab-manufactured temporary prosthesis) and agreed on the chair-side fabrication of a long-term temporary bridge (bridge abutments 22, 21, 12) using the semi-permanent composite material LuxaCrown in a session together with the tooth extraction.

TREATMENT

After anesthetizing tooth 11 a pre-operative impression was taken (Fig. 5). The impression was trimmed at the edges using a scalpel and the impression material in the area of diastemas 11–21 has removed (Fig. 6). The crowns on teeth 12–22 were removed and tooth 11 extracted (Fig. 7). The extraction wound was sealed with two individual button sutures and the caries lesions on

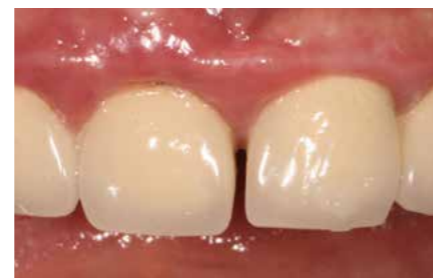

Fig. 1: Initial situation frontally.

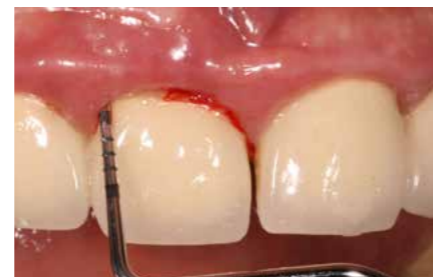

Fig. 2: Deep periodontal pocket on tooth 11.

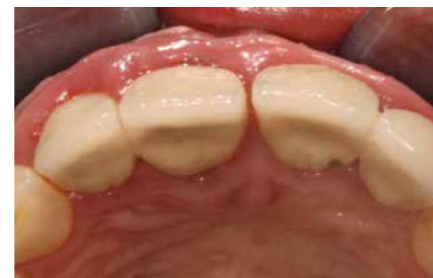

Fig. 3: Initial situation incisally.

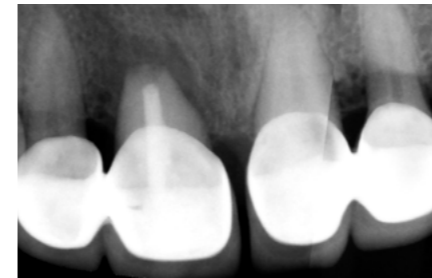

Fig. 4: X-ray image of maxilla front.

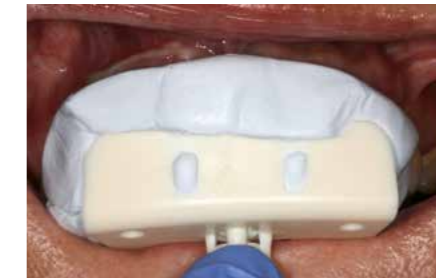

Fig. 5: Pre-operative impression in-situ.

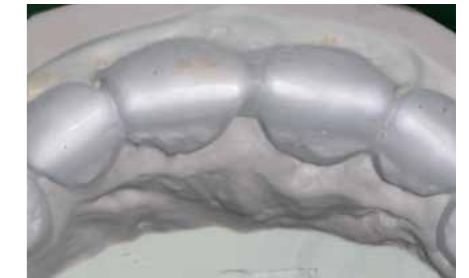


Fig. 6: Pre-operative impression after trimming.

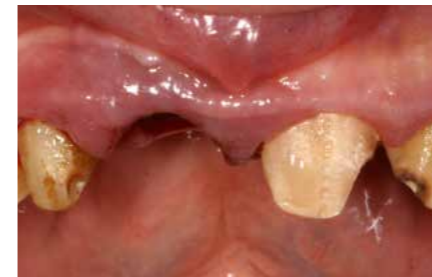

Fig. 7: Situation after removal of crowns and extraction of tooth 11.

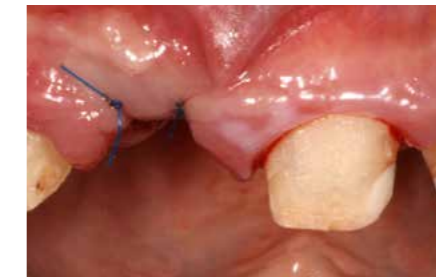

Fig. 8: Provision of caries lesions with fillings.

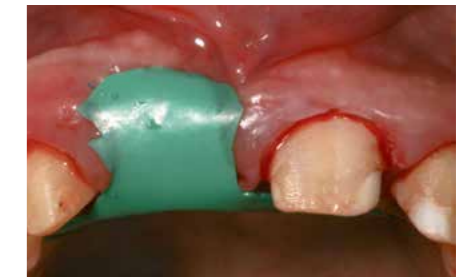

Fig. 9: Coverage of extraction wound with rubber dam.

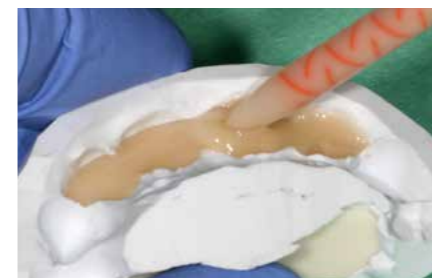

Fig. 10: Filling of the restoration impression with LuxaCrown.

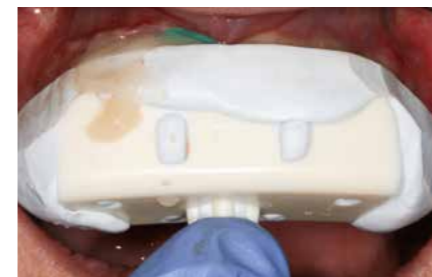

Fig. 11: Reinsertion of the filled restoration impression.

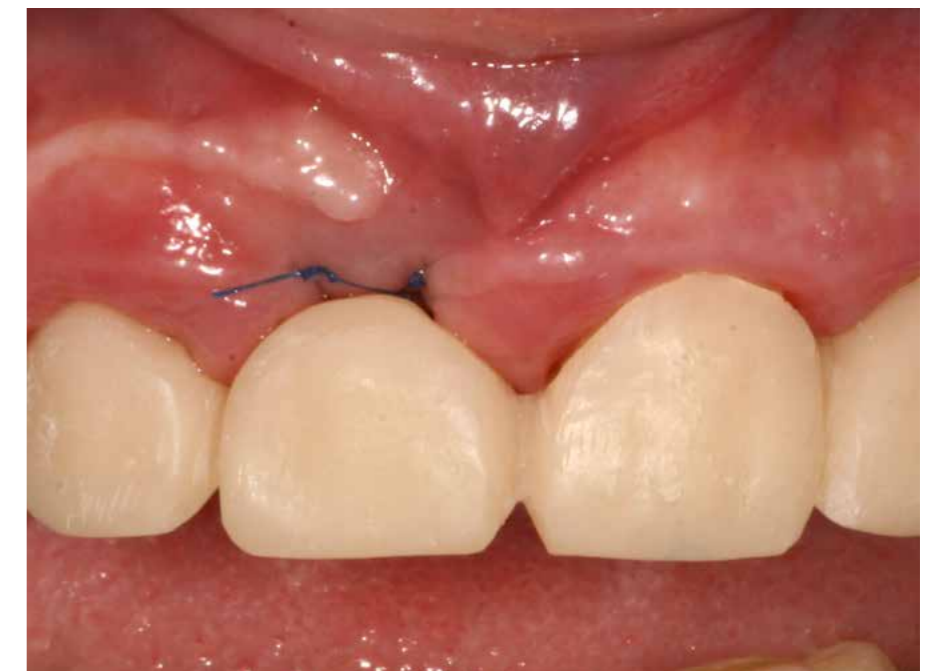

Fig. 12: Check of the fit of the roughly finished restoration frontally.

the bridge-abutment teeth stumps were provided with fillings (Fig. 8). In order to prevent the composite from penetrating into the fresh extraction wound in its free-flowing state, the wound was covered with a piece of rubber dam (Fig. 9).

The pre-operative impression was filled with LuxaCrown (Fig. 10) and replaced into the mouth (Fig. 11).

The setting process was monitored intraorally on a bit of excess composite using a probe and the restoration removed from the mouth in an elastic but not yet fully set state.

After complete curing extraorally, the temporary bridge was roughly finished with a cross-cut tungsten carbide burs and the correct fit and occlusion checked intraorally (Figs. 12).

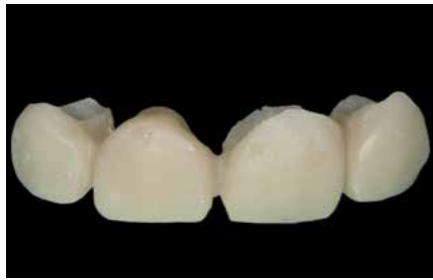

Fig. 13: Restoration after final finishing.

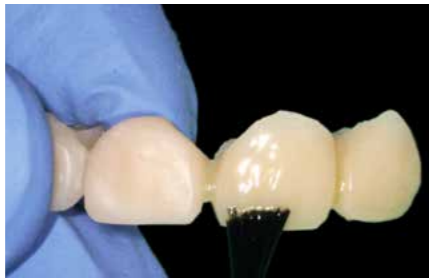

Fig. 14: Application of Luxatemp Glaze & Bond surface sealant.

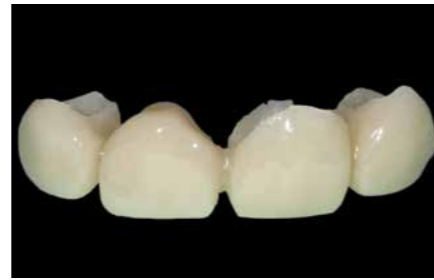

Fig. 15: Restoration after surface sealing.

The final finishing was done using wheels of varying grains (Fig. 13). In order to seal the surface of the temporary bridge and to give the teeth a natural-looking shine, a thin layer of Luxatemp-Glaze & Bond was applied and light-cured (Figs. 14 and 15). A temporary luting cement was used for insertion. After light-curing, excess cement was removed with a scaler and the patient discharged from treatment (Fig. 16).

One week later the patient returned to the clinic for suture removal. Inflammation-free gingival conditions were apparent on inspection of the temporarily restored teeth (Fig. 17).

The patient was symptom-free and satisfied with the results of the treatment.

CONCLUSION

The semi-permanent composite material LuxaCrown makes it possible to manufacture robust long-term temporaries with materials and techniques available in most dental practices.

In combination with the surface sealant Luxatemp-Glaze & Bond it enables the fabrication of highly esthetic restorations, in line with the expectations of patients, particularly in the visible area.

CONTACT

Dr. Gerd Göstemeyer
Charité University Medical
Institute Restorative and Preventive Dentistry
Alßmannshäuser Str. 4-6
14197 Berlin
Germany

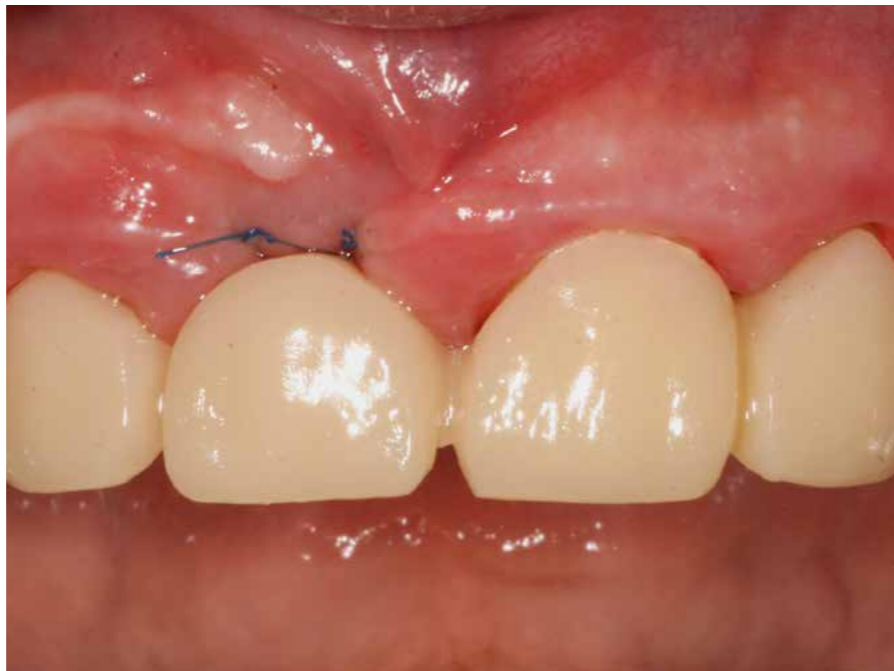

Fig. 16: Restoration after insertion.

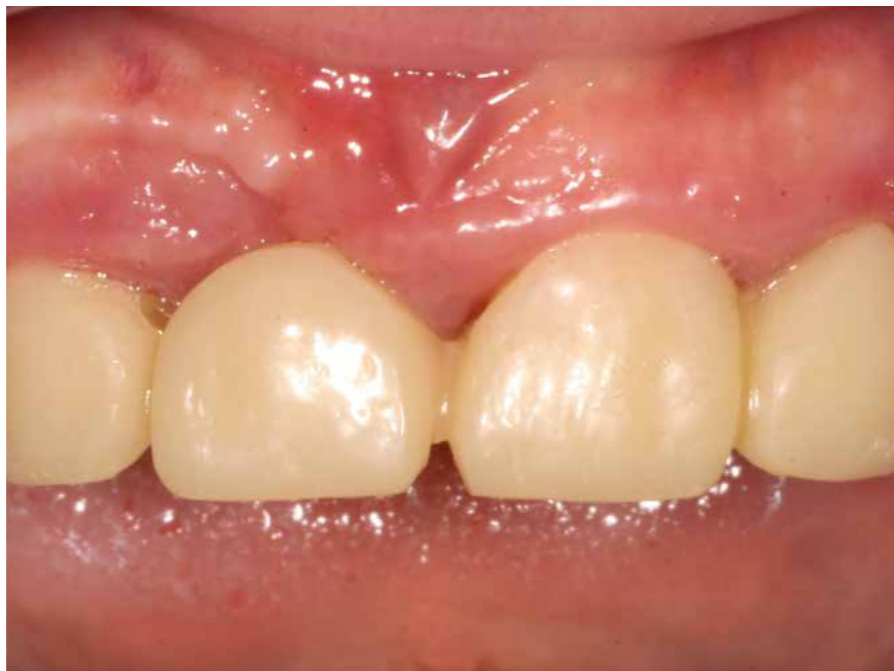

Fig. 17: Restoration during check-up after a week.

Semi-permanent restoration – a preview of definitive treatment.

Dr. Mirko Christian, Dentist Christian Grünler, Dentist Linda Wolf, Germany

The purpose of dental prosthetics is to restore the chewing function with special consideration of articulation and the aesthetic. This applies not just to the definitive treatment but, to an increasing extent, also to temporary restorations which, in fixed crown or bridge form, can be produced chair-side by the dentist.

As well as protecting the tooth which, as a result of the loss of hard tooth tissue associated with the preparation, reacts sensitively to chemical, thermal or mechanical irritations, a fixed temporary solution also serves to temporarily restore the shape and color of the tooth anatomy, thereby allowing the patient a preview how the future restoration will look.

With this in mind the choice of the right material that meets the growing requirements for function and aesthetic becomes more important.

CASE REPORT:

The 73 year-old patient presented herself to the Dental Clinic 2 – Dental Prosthetics – of the University Hospital Erlangen-Nuremberg (Director: Prof. Dr. M. Wichmann) with a request for prosthetic restoration of the upper jaw. On analysis of the dental findings, it was discovered that the lower jaw had been sufficiently restored with attachment work. In the upper jaw there was a temporary denture in place for 13-23 that had been in-situ for

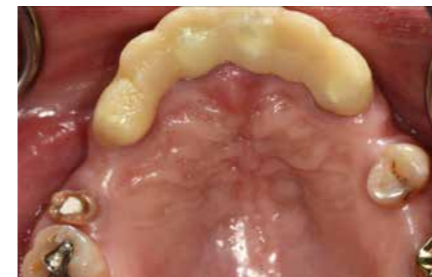

Fig. 1: Initial situation maxilla from occlusal.

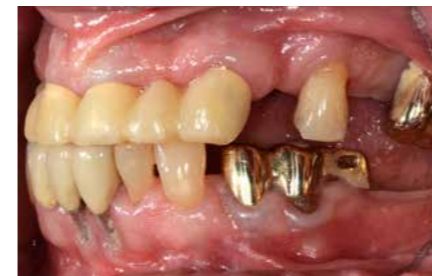

Fig. 2: Initial situation 4th quadrant buccal.

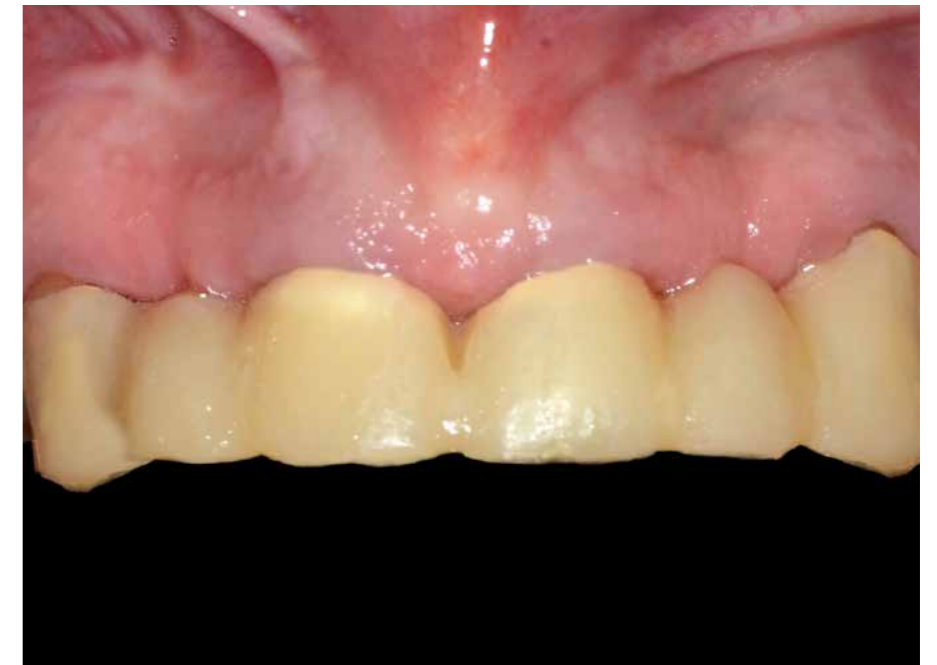

Fig. 3: Initial situation maxilla front.

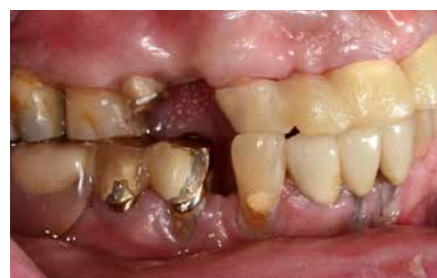

Fig. 4: Initial situation 3rd quadrant buccal.

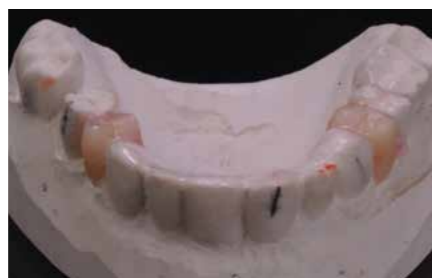

Fig. 5: Augmented situation model.

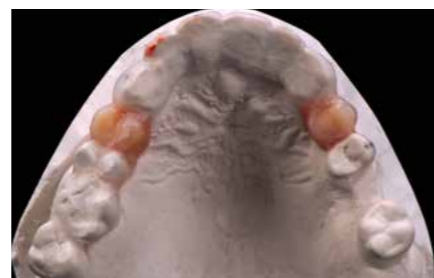

Fig. 6: Augmented situation model.

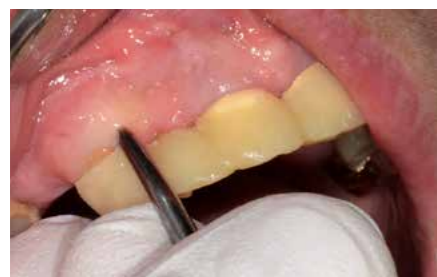

Fig. 7: Old temporary extracted with crown remover.

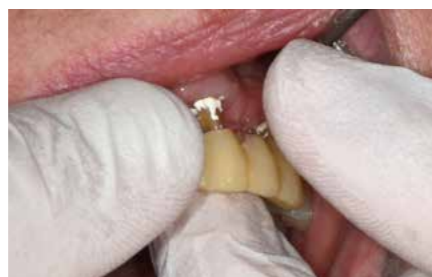

Fig. 8: Removal of the old temporary.

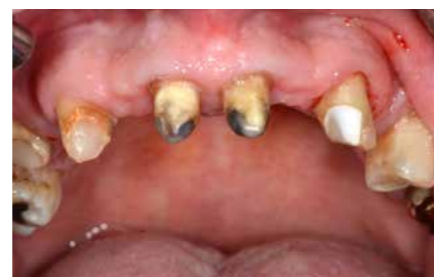

Fig. 9: Prepared abutments 13, 11, 21, 23.

more than two years. The patient was very dissatisfied with the aesthetic of the temporary denture, both in terms of the shape of the tooth and the color.

The clinical findings also revealed insufficient crown margins on all the pillars. The x-ray check indicated sufficient endodontic treatment of teeth 11, 21 and 23. Tooth 23 however exhibited a slight apical tenderness on palpation from the vestibular surface, which may be down to the insufficient temporary denture (Figs. 1-4).

The gaps at 14, 24 and 26 were not restored. The clinical crown of tooth 15 was no longer in place, the remaining hard tooth tissue is worth preserving with an endodontic treatment and post build-up. Following an analysis of the initial situation and the creation of situation models (Figs. 5 and 6), a decision was made to first incorporate a sufficient semi-permanent restoration at the front, since there were doubts as to the preservation of tooth 23 and a definitive prosthetic restoration would depend directly on this.

To create the semi-permanent restoration a vacuum-formed template in which the gaps at

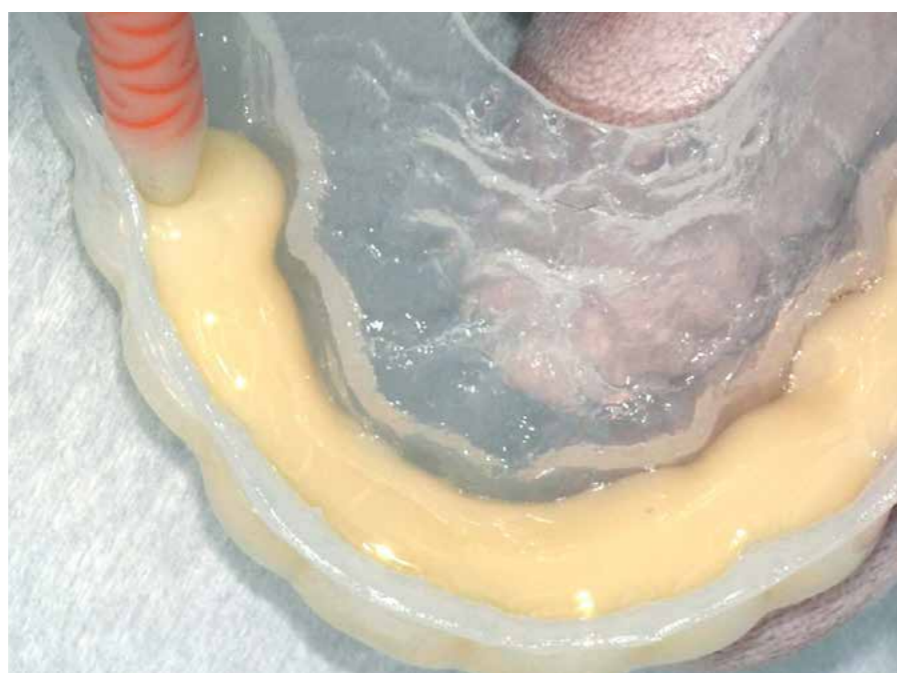

Fig. 10: Vacuum-formed stent filled with LuxaCrown without any air bubbles.

14 and 24 were replaced was manufactured in the lab. Following the removal of the old temporary denture (Figs. 7 and 8), an assessment was made of the prepared stumps 13, 11, 21 and 23 (Fig. 9). To increase the layer thickness all pillars were prepared again in chamfer form. Afterwards the later tooth shade A3 was selected using the VITA shade scale. After relative drainage and cleaning of the stumps with ethanol the vacuum-formed template was filled evenly and without any bubbles with LuxaCrown (DMG, Hamburg) from 15 to 25 before being inserted into the mouth of the patient (Figs. 10-12).

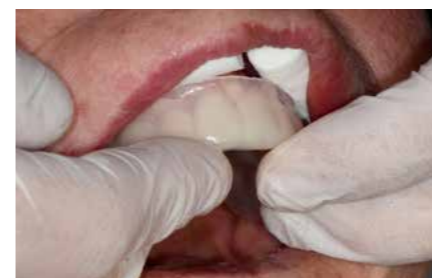

Fig. 11: Intraoral fabrication of the restoration.

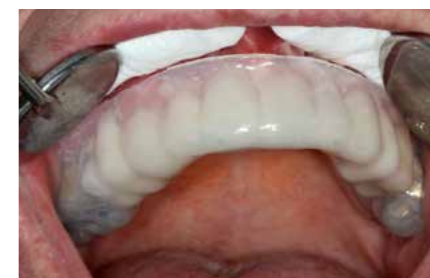

Fig. 12: The restoration is left on the cores to polymerize.

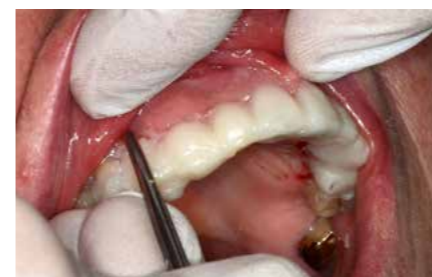

Fig. 13: Removal of the cured restoration.

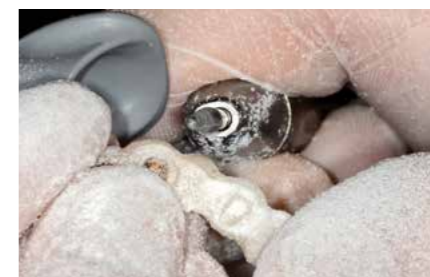

Fig. 14: Machining the restoration.

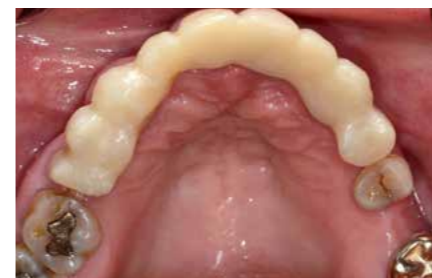

Fig. 15: Complete LuxaCrown restoration in occlusal view.

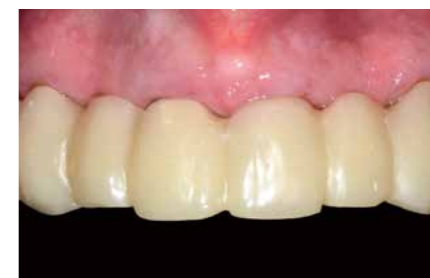

Fig. 16: Complete LuxaCrown restoration in frontal view.

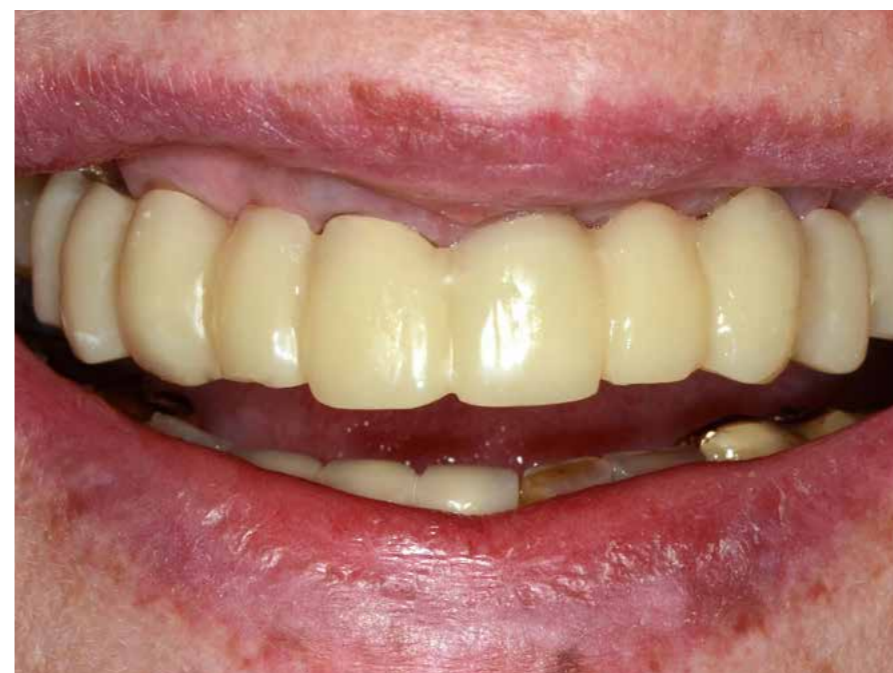

Fig. 17: Complete LuxaCrown restoration in frontal view.

After two minutes the template was removed, leaving the restoration on the stumps, following which any excess was roughly removed with a scaler (Fig. 13). Only at this point was the restoration removed and repositioned. The removal of the fully cured restoration took place after five minutes.

The next step included the extraoral shaping and preparation of the restoration by resin milling (Fig. 14). The papilla-appropriate shaping of the interdental spaces was done using cutting discs. Subsequently to that, the restoration was reworked with the aid of goat's hair brushes, a wool wheel and polishing paste.

Finally surface sealing was performed with Luxatemp-Glaze & Bond (DMG, Hamburg) to restore a natural, enamel-like sheen and also to reduce plaque retention. After the final examination of the aesthetic as well as occlusion and articulation, the restoration was inserted with TempoCem NE (DMG, Hamburg) (Figs. 15-17).

The patient will wear the semi-permanent restoration until the preservation of tooth 23 can be assessed. During this time follow-up appointments will take place because the semi-permanent restoration can give advance insight into how any potential later restoration might look and so consultation can take place with the patient. Potential changes in terms of shape and shade are possible in this time, meaning that the patient can develop a clear expectation of what the future restoration will look like.

CONTACT

Dr. Mirko Christian
Dentist Christian Grünler
Dentist Linda Wolf
University Hospital Erlangen
Dental Clinic 2 – Prosthodontics –
Glückstraße 11
91054 Erlangen
Germany

Semi-permanent restoration – functional and esthetic success.

Dr. Mirko Christian, Dentist Christian Grünler, Dentist Linda Wolf, Germany

The main purpose of dental prosthetics is the restoration of a functional chewing function. The past few years have seen a clear tendency for rising patient demands when it comes to dentures, not only with regard to optimum function but aesthetic appearance too. For that reason it is becoming increasingly important for the pursued treatment objective to be clearly defined and, ideally, demonstrated to the patient beforehand. Manufacturing high-quality temporary restorations firstly allows initial aesthetic analyses to take place and, secondly, provides optimum protection of the prepared tooth against thermal, chemical and mechanical irritations.

CASE REPORT

The 56 year-old patient presented with a gap situation in the 1st quadrant. Teeth 14, 16 and 17 have been missing for several years. The primary desire of the patient was the restoration of a sufficient chewing function, the denture was also to be as unobtrusive as possible and fit in with the overall aesthetic appearance of the patient.

Tooth 15 has been restored with an extended insufficient MOD filling. The patient indicated that she has no symptoms.

The radiographic overview does not show any apical illumination. Following an analysis of the initial situation and the production of

situation models, plans were made for the definitive restoration. The aim is a fixed dental prosthesis. Following consultation with the patient, plans were made for a bridge at 13-15 with distal supports at 16. For the material a full-ceramic restoration with zirconium oxide frame and full ceramic veneer was selected. Initially tooth 14 was to be added on the situation model in the dental lab (Fig. 1).

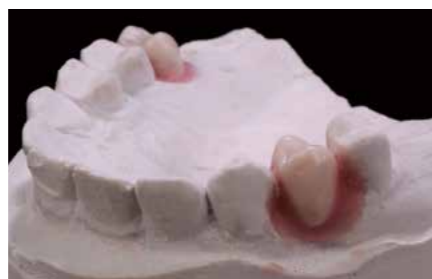

Fig. 1: Situation model with prosthetic teeth in position.

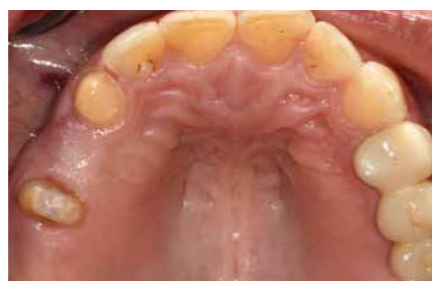

Fig. 3: Prepared cores 13 and 15 from occlusal.

A vacuum-formed template of the now closed row of teeth was also created on the situation model (Fig. 2). For structural reasons the replacement of tooth 16 was dispensed with initially in the temporary restoration. In the first treatment session the insufficient MOD-filling on tooth 15 was replaced. The color for the restoration and for the subsequent restoration was defined using th

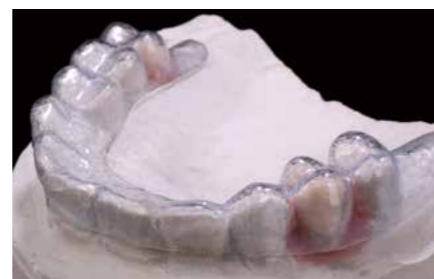

Fig. 2: Situation model with prosthetic teeth in position with vacuum-formed stent.

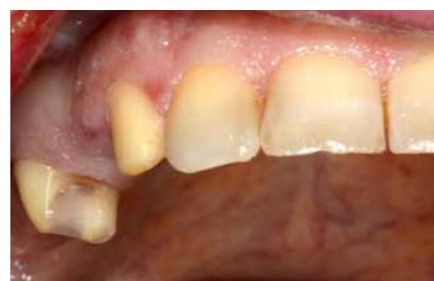

Fig. 4: Prepared cores 13 and 15 from frontal.

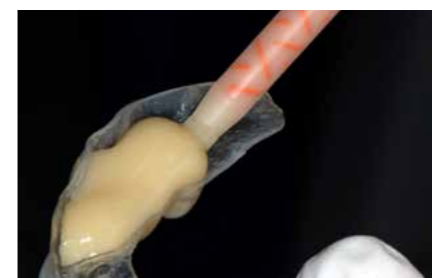

Fig. 5: Filling LuxaCrown into the stent.

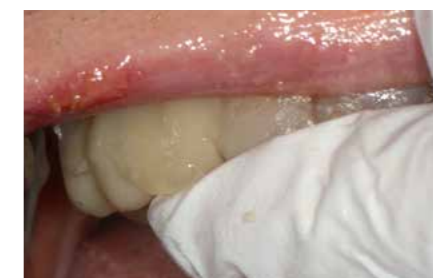

Fig. 6: Stent with LuxaCrown inserted.

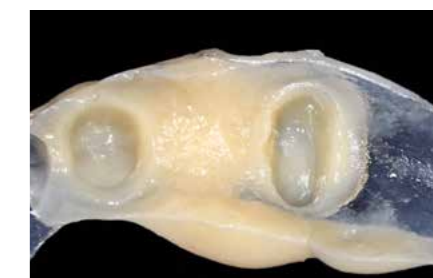

Fig. 7: Restoration left in the stent to cure.

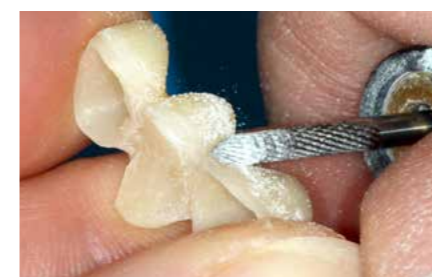

Fig. 8: Preparing the restoration with milling device.

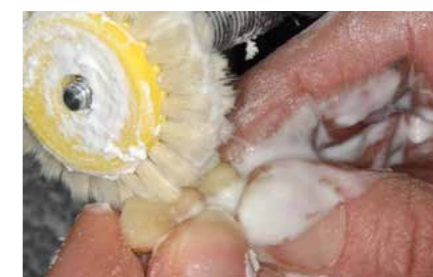

Fig. 9: Preparing the restoration with pumice powder.

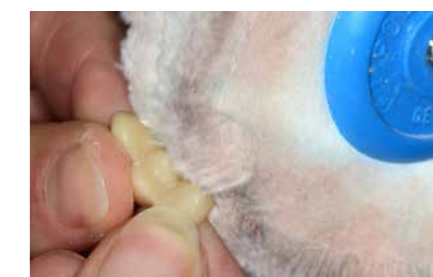

Fig. 10: Pre-polishing with cloth wheel and universal polishing paste.

VITA shade scale. Then a minor subgingival chamfer preparation was performed on both bridge pillars, during which the key emphasis was on a common insertion direction and rounded edges (Figs. 3 and 4).

The vacuum-formed template prepared beforehand in the lab was filled evenly and without any bubbles with LuxaCrown (DMG, Hamburg) and inserted into the patient's mouth (Figs. 5 and 6). After two minutes in situ the restoration, which is in the elastic phase, was removed from the mouth.

The restoration remained in the vacuum-formed template until it has reached final hardness (Fig. 7). After removing any rough excess, the temporary restoration was repositioned to check the fit and shade intraorally. Before continuing work on the restoration, the oxygen inhibition layer was removed from its surface with ethanol. The rough workmanship took place extraorally with a cross-toothed mill and pumice powder (Figs. 8 and 9). Particular emphasis is placed on the interdental arrangement and a precision marginal fit. The pre-polishing is carried out with the help of a linen wheel and universal polishing paste (Fig. 10).

To achieve the maximum aesthetic result and give the surface a natural sheen, Luxatemp-Glaze & Bond (DMG, Hamburg) was applied, spread evenly and light-cured. This type of

surface sealing also reduces excessive plaque formation and provides protection from discoloration (Fig. 11).

To create a definitive restoration a corrective impression of the upper jaw, an opposing jaw impression and a bite registration were created and sent to the dental lab for further workmanship. Then the restoration was inserted with TempoCem NE (DMG).

After checking the proximal contact, the articulation and occlusion the patient was discharged satisfied.

A trial fitting is planned for the next appointment, during this specific requests of the patient which came up while wearing the semi-permanent restoration can be taken into account (Figs. 12 and 13).

CONTACT

Dr. Mirko Christian, Dentist Christian Grünler, Dentist Linda Wolf
University Hospital Erlangen
Dental Clinic 2 – Prosthodontics
Glückstraße 11, 91054 Erlangen
Germany

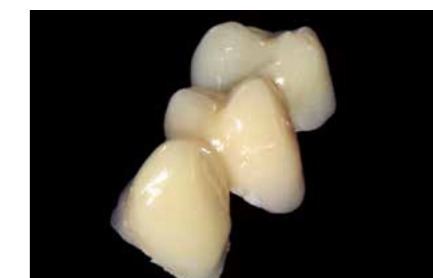

Fig. 11: Completion of the semi-permanent LuxaCrown restoration with Luxatemp-Glaze & Bond.

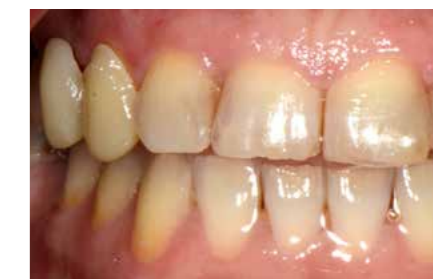

Fig. 12: Inserted semi-permanent LuxaCrown restoration from frontal.

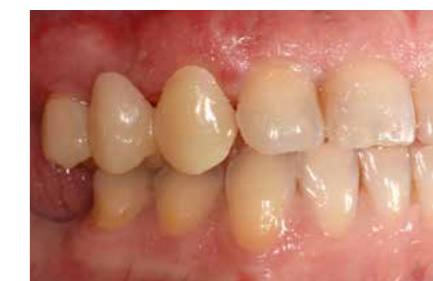

Fig. 13: Inserted semi-permanent LuxaCrown restoration from buccal.

Semi-permanent fixed dental prostheses to optimize the treatment result.

Dentist Lars Ahlskog, Dr. med. dent. Katharina Kuhn, Germany

The original purpose of temporary crowns and bridges is to perform replacement, protective and stabilization functions.

A temporary dental prosthesis replaces the removed tooth substance to temporarily restore esthetics, phonetics and masticatory function. The prepared hard tooth tissue and thus the pulp too have to be protected.

The dental arch is also stabilized and tooth migration can be prevented until the definitive dental prosthesis is inserted as promptly as possible. Conventional materials for fabricating temporaries are designed to remain in the mouth for a short time according to these requirements. With new highly esthetic, ceramic materials for definitive fixed dental prostheses, both patients' and dentists' expectations with regard to the esthetic end result have increased.

In addition to the precise technical design requirement to achieve gap-free crown edges where possible, the optimization of the esthetic treatment result has increasingly been in the focus of attention.

As well as the tooth color, the tooth shape also plays a major role when it comes to improving white esthetics. Particularly tooth remodeling such as crown lengthening and/or crown widening often go hand in hand with substantial changes as regarding appearance of the patient.

It is therefore advisable to have them firstly try out the anticipated tooth shape for a certain period of time in form of a semi-permanent, temporary restoration. During this time, the patient can form an opinion on the new tooth shape, whereby feedback from the people around them (family, friends, colleagues) are naturally always influential too.

Desired changes can be implemented through modifying the form of the semi-permanent dental prosthesis. This approach increases the certainty of treatment success and meets both the patient's and the practitioner's need for predictability of the final result.

Red esthetics meaning soft tissue that appears as perfect as possible in terms of path, color and texture is the second cornerstone of esthetic success.

Besides surgical measures to optimize the red esthetics, soft tissue can also be influenced through prosthodontic means. The position of the point of interproximal contact, for instance, influences the papilla's architecture. Because the soft tissue's reaction is subject to high interindividual variations, generally speaking it is impossible to predict the extent to which the soft tissue can be influenced with surgical and/or prosthetic measures.

Once the individually achievable shaping of the marginal soft tissue is complete, the definitive dental prosthesis to be newly made

can be optimally designed in an appropriate manner, so as to purposefully strive to compensate for esthetic limitations.

During the soft tissue shaping stage, a temporary restoration which can be altered relatively easily to gradually support soft tissue modeling is provided. Due to the often substantial time periods until marginal soft tissue shaping is complete, in these cases materials for semi-permanent restorations should be used. These pretreatment

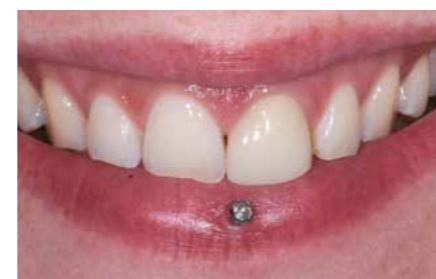

Fig. 1: Initial situation for the frontal view (when smiling).

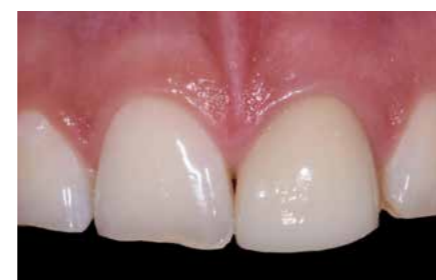

Fig. 2: Initial situation for the frontal view (close-up view).

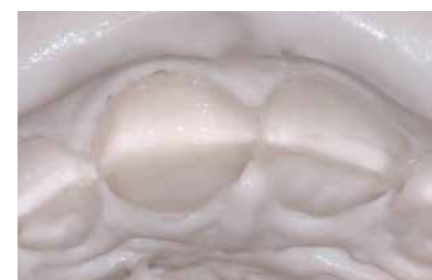

Fig. 3: Mold created from alginate..

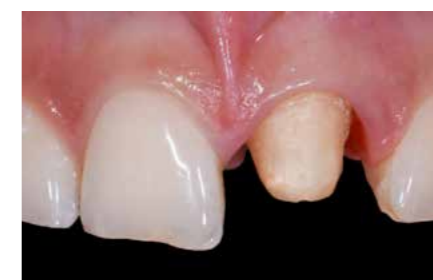

Fig. 4: Condition following removal of the old crown.

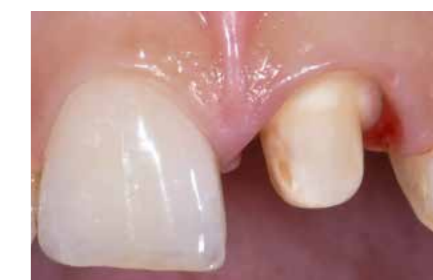

Fig. 5: Condition following post-processing.

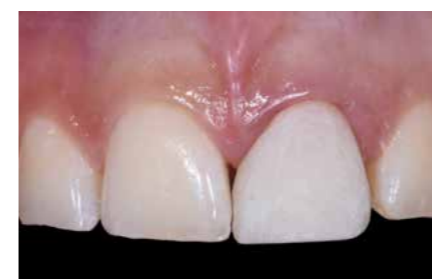

Fig. 6: Temporary crown following rough preparation.



Fig. 7: Application of Luxatemp-Glaze & Bond.

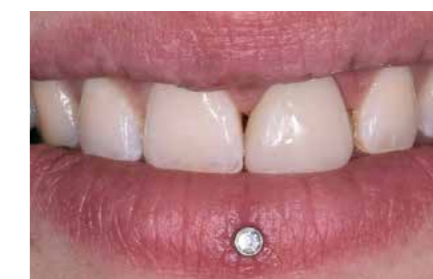

Fig. 8: Semi-permanent crown 21 straight after insertion, frontal view (when smiling).

strategies listed above to create natural, healthy appearing red and white esthetics demand enhanced materials for temporary restorations and result in an request for performing original replacement, protection and stabilization functions.

This results in requests for – semi-permanent – temporary materials that can be used over a longer period of time, in combination with a high level of biocompatibility and ongoing simple handling in fabrication and redesign.

INITIAL SITUATION

A 25-year old patient presented herself with an all-ceramic crown inserted three years ago on vital tooth 21 (Figs. 1 and 2).

The crown had decemented itself four times since incorporation. An insufficient fit was documented during the last recementation process. In addition to these technical aspects, the patient wasn't satisfied with the esthetic appearance of the restoration. Following a dental examination, it became apparent that there was a lack of distal proximal contact and proximal damage to the biological width was an additional point of criticism as regards the technical design.

At the insufficient crown margin, mild circular gingivitis with an interproximal tendency to bleed and accordingly inflamed, red

discoloration of the gingiva were determined. Furthermore the relatively wide base of the fixed restoration had induced to much pressure on the mesial papilla which had caused a "black triangle" in the interproximal space between tooth 11 and 21.

During treatment using a semi-permanent restoration, analyzing white esthetics, it became apparent that there was asymmetry, because crown 21 had a greater mesio-distal width than tooth 11.

AIMS

For the restoration of tooth 21 with an all-ceramic fixed dental prosthesis, the following objectives regarding the technical design were defined by the practitioner in conjunction with the patient. A suitable proximal contact was to be created distally even in the temporary restoration to protect the distal papilla. All efforts served the purpose to restore and support healthy conditions of the marginal gingiva. Relieving the papilla of unnecessary pressure implementing a more slender emergence profile was to achieve a better papilla fill between the central incisors and close the black triangle.

The mesio-distal width of crown 21 was to be reduced to optimize the shape of the crown. The width of the lateral incisor 22 was to be mesially corrected slight using composite layering technique.

IMPLEMENTATION

Before removing old crown 21, a mold (Fig. 3) was created from alginate for subsequent fabrication of the temporary crown. Since the old fixed dental prosthesis was oversized, redesigning the form of the temporary restoration involved only subtractive measures. Cut back on the alginate mold was therefore not performed.

Post-preparation took place once the crown had been removed (Figs. 4 and 5). Once the crown had been removed care was taken to avoid placing the margin any deeper and to increase the retention of the restoration during preparation of abutment tooth 21.

To clarify the ideal crown shape for an esthetically appealing restoration and to shape the soft tissue, a semi-permanent material was chosen for fabrication of the temporary restoration. The material LuxaCrown in the color B1 (DMG, Hamburg) was casted into the mold and placed without any bubbles and placed in the patient's mouth. After two minutes the mold was removed.

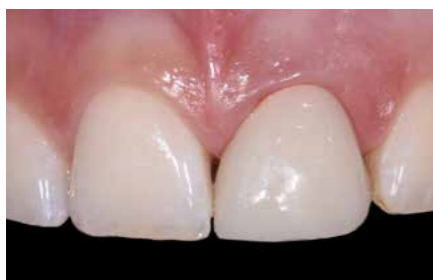

Fig. 9: Semi-permanent crown 21 straight after insertion, frontal view (close-up view).

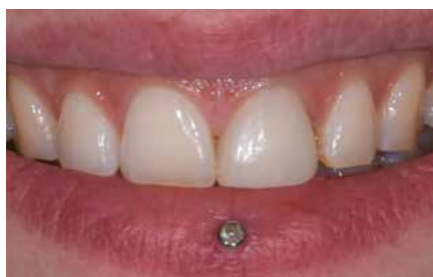

Fig. 10: Semi-permanent crown 21 one week after insertion, frontal view (when smiling).

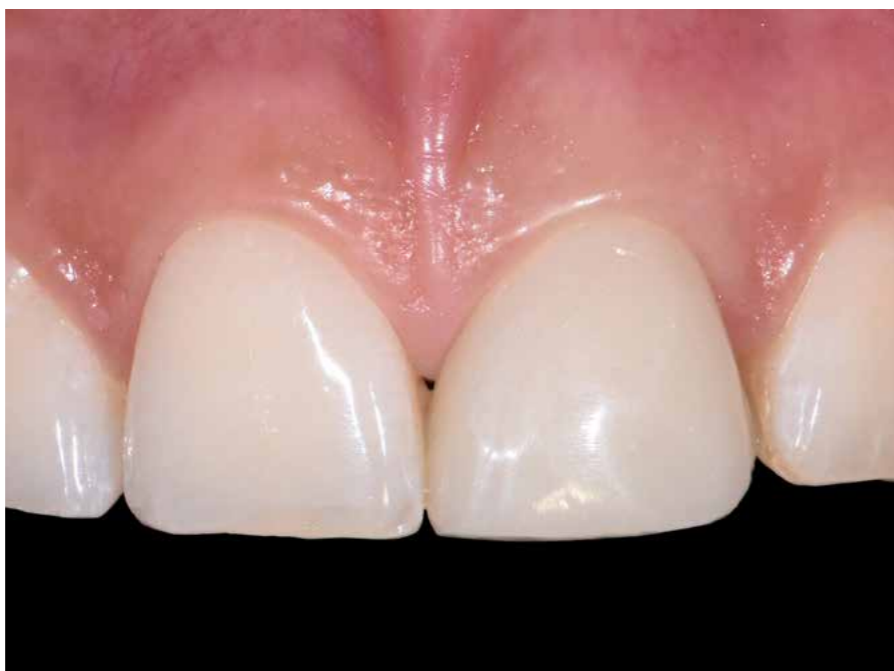

Fig. 11: Semi-permanent crown 21 one week after insertion, frontal view (close-up view).

The temporary restoration remained on the abutment tooth during this process. Final shaping was performed using flexible discs. Rough preparation of the temporary crown took place first of all, whereby streaks and any excess material were removed, the oversized crown edge design was thinned out and the width of the crown base was reduced slightly (Fig. 6).

Once preparation was complete, Luxatemp-Glaze & Bond (DMG, Hamburg) was applied to the seal to create shine and optimize the surface quality (Fig. 7).

The temporary crown was inserted with a temporary luting cement (Figs. 8 and 9).

When the patient presented herself one week later, the red esthetics had already improved significantly. The mesial papilla had already developed incisally and the “black triangle” had almost completely closed (Figs. 10 and 11). Also, the slight inflammation with reddened gingiva had gone down. This rapid improvement is a clear argument in favor of the biocompatibility of the temporary material used with the patient’s individual and particularly pronounced regenerative capacity. As a further step, the lateral incisor was even widened with composite to narrow crown 21 accordingly and to adapt it to the width of tooth 11. The semi-permanent LuxaCrown

restoration can be easily redesigned in the dentist’s chair. The fabrication and insertion of the definitive crown takes place as soon as both the patient and the practitioner are satisfied with the esthetic pretreatment result with a semi-permanent crown restoration and would like to transfer this condition to a definitive restoration.

CONCLUSION

With the semi-permanent restoration, it was possible to optimize the conditions for the definitive crown restoration to achieve the patient’s and the practitioner’s esthetically demanding aims. In this case, the soft tissue situation improved rapidly.

Particularly in the event of prosthetic treatment cases with less favorable conditions (e.g. bone resorption with recessions) and thus longer waiting times for soft tissue remodeling, a semi-permanent temporary restoration is all the more relevant. During the entire wearing period, by means of the temporary restoration’s design it is possible to gradually and specifically influence soft tissue development and, at the same time, to test the acceptance of esthetic remodeling.

This approach requires a temporary restoration material with semi-permanent properties, so as to tide over the time until the

definitive restoration with a temporary dental prosthesis that is of as high a quality as possible is inserted.

CONTACT

Dentist Lars Ahlskog
Dental Practice
Möhringerstraße 77
78532 Tuttlingen
Germany

Dr. Katharina Kuhn
University Hospital Ulm
Clinic for Dental Prosthetics
Albert-Einstein-Allee 11
89081 Ulm
Germany

Cost effective, esthetic, long term temporary crowns.

Prof. Dr. Neeraj Gugnani, India

Caries and trauma are amongst the leading causes resulting in the loss of tooth structure that mandate the restoration of tooth for esthetics and proper functioning.

These restorations can be either intra-coronal or extra-coronal depending upon the amount of tooth structure lost. Such teeth also frequently get pulpally involved thus requiring endodontic treatment. Following endodontic therapy, the remaining tooth structure becomes weak and brittle to withstand the masticatory load, which further necessitates the need for an extra-coronal restoration.

The common materials used for fabrication of crowns are acrylic, porcelain/ceramic and zirconia. These crowns exhibit varying success rates and besides the dentist’s or patient’s preference there are other factors that may limit their use. These include technique

sensitivity, requirement of multiple visits to dentist and high cost in case of zirconia and PFM crowns and also compromised esthetics in PFM crowns due to its metal framework.

Moreover, due to various reasons like time constraint, higher cost of the crowns etc., patient defers the crown restorations.

Consequently a restorable tooth may gradually fracture and may become non-restorable. Thus, there has always been a quest to create a crown material which is esthetic, cost-effective, easy to fabricate, less technique sensitive, durable and be able to bear the masticatory load without wearing off significantly and should stay in service for a much longer time compared to any provisional restoration.

LuxaCrown – a composite based material can be used to make such long term esthetic temporary

crowns and bridges – called as long term temporaries or semi-permanent restorations. These can be used in situations when patients require a single sitting, esthetic and cost-effective solution for their full-coronal restoration needs and also whenever the dentist feels the clinical need for a long term temporary esthetic crown including the ones for immediate implant loading etc.

CASE 1

A 26 year old male patient reported with a chief complaint of long standing fracture of maxillary right central incisor which exposed the dentin and was not restored at the time of injury. Patient reported after four years of trauma and the tooth was found to be non-vital (Fig. 1).

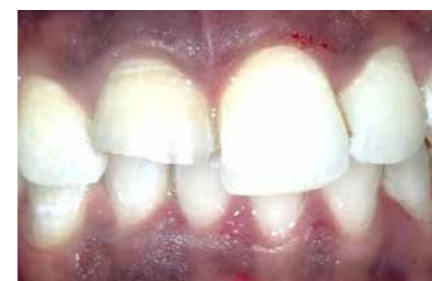

Fig. 1: Pre-operative situation.

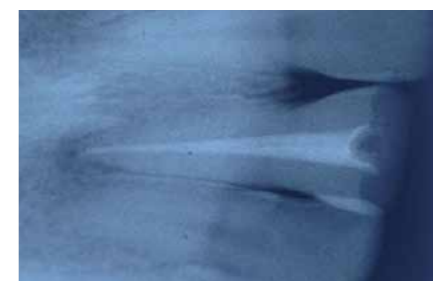


Fig. 2: RCT with 11.

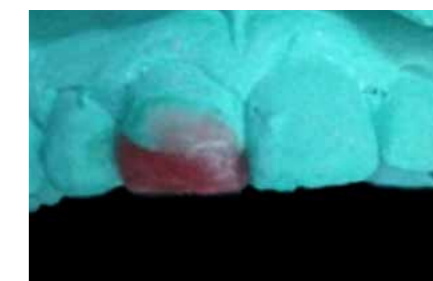


Fig. 3: Wax mock up.

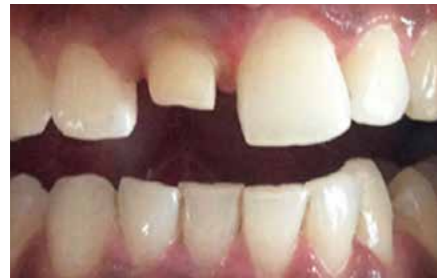

Fig. 4: Tooth Preparation.

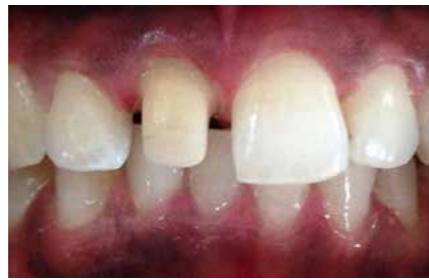

Fig. 5: Build-up of tooth structure.

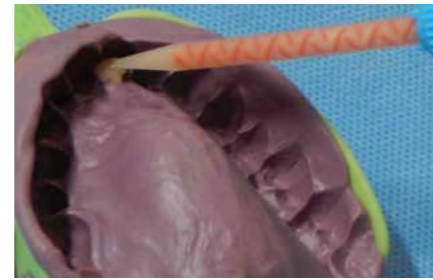


Fig. 6: Impression loading with LuxaCrown.

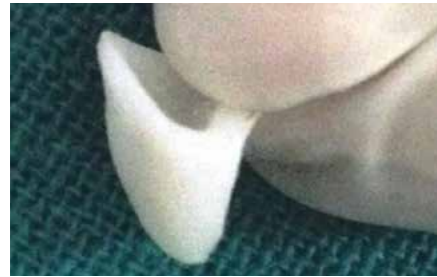

Fig. 7: Finished LuxaCrown.

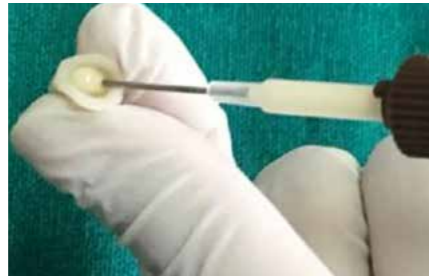


Fig. 8: Cementation of LuxaCrown.

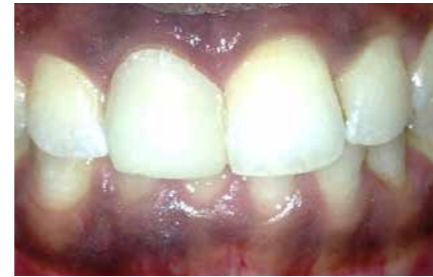

Fig. 9: Cemented LuxaCrown.

Initially root canal treatment was completed using the standardized procedure (Fig. 2) which was followed by Crown fabrication. As the patient was not able to afford a zirconia or PFM crown, a long-term temporary was planned using LuxaCrown (DMG, Germany). As there was some loss of tooth structure, initially the impression was taken and cast was fabricated for wax mock-up of the tooth so as to simulate the natural tooth anatomy (Fig. 3). An impression of the cast was taken using the polysiloxane elastomeric impression material and secured aside.

Meanwhile crown cutting was done using the standardised principles of tooth preparation (Fig. 4). To increase the inciso-gingival length of the remaining tooth structure, composite build-up was done at the incisal level (Fig. 5). Following this, the LuxaCrown material was loaded in the impression using the Automix syringe and the impression was reloaded in the patient's mouth (Fig. 6). The impression was allowed to stay there for about 2 minutes – to allow the partial setting of the LuxaCrown material. The impression was then taken out and the material was

allowed to set outside patient's mouth for approximately 5 minutes from the start of mixing. The crown was then removed from the impression and was finished using fine composite burs to cut off any excess flash. The Crown was then finished using a fine buff and pumice, followed by application of Luxatemp-Glaze & Bond (DMG, Germany) (Fig. 7). The crown fabricated was then cemented using PermaCem 2.0 luting cement (DMG, Germany) (Fig. 8) resulting in a good esthetic restoration with great patient satisfaction (Fig. 9).

CASE 2

A 17 year old male patient reported with a chief complaint of compromised esthetics in the upper front region of the jaw. On examination the patient was observed to be having non-pitted fluorosis while caries on the palatal aspect of 11 and 21 (Figs. 1 and 2). IOPA X-ray of 11 and 12 showed pulpal involvement of 11 while dentinal caries in 12. In accordance, Maxillary right central incisor was treated with RCT (Fig. 3).

Tooth 12 was restored from palatal aspect using an intra-coronal restoration with composites while on facial aspect Resin infiltration was done using Icon (DMG, Germany) for esthetic improvement of the non-pitted brown discoloration due to fluorosis. Further a full coronal restoration was planned for RCT treated upper right central incisor. For this initially a maxillary impression was taken using polysiloxane elastomeric impression material.

Crown cutting was done using the standardised principles of tooth preparation (Fig. 4). Following this the LuxaCrown material was loaded in the impression using the Automix syringe and the impression was reloaded in the patient's mouth (Fig. 5). The impression was allowed to stay there for about 2 minutes – to allow the partial setting of the LuxaCrown material. The impression was then taken out and the material was allowed to set outside patient's mouth for approximately 5 minutes from the start of mixing. The crown was then removed from the impression and was finished using fine composite burs to cut off any excess flash. The Crown was then finished using a fine buff and pumice, followed by application of Luxatemp-Glaze & Bond (DMG, Germany) (Fig. 6). The crown fabricated was then cemented using PermaCem 2.0 luting cement (DMG, Germany) resulting in a good esthetic restoration with great patient satisfaction (Fig. 7).

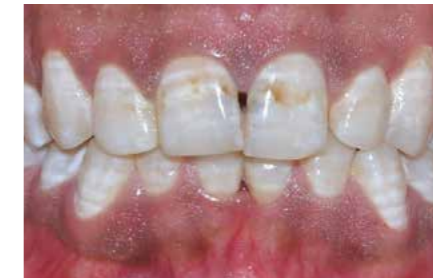

Fig. 1: Pre-operative situation.

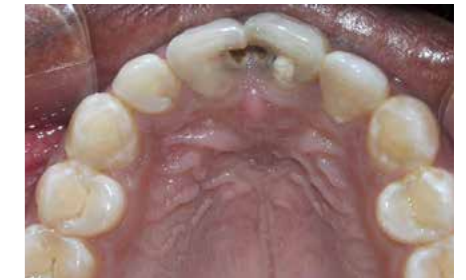

Fig. 2: Pre-operative situation.

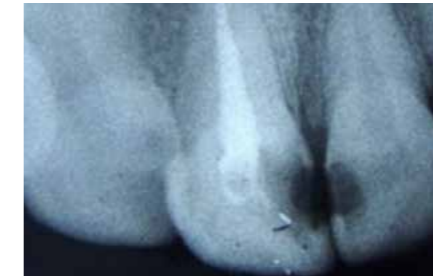

Fig. 3: RCT with 11.

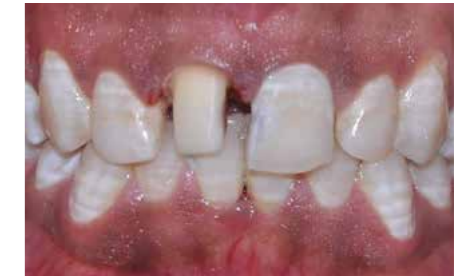

Fig. 4: Tooth preparation.

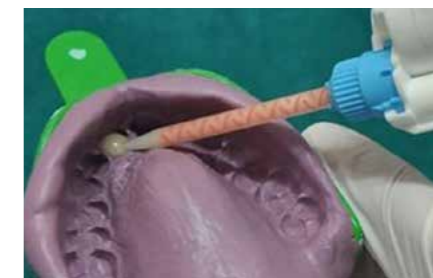

Fig. 5: Impression loading with LuxaCrown.

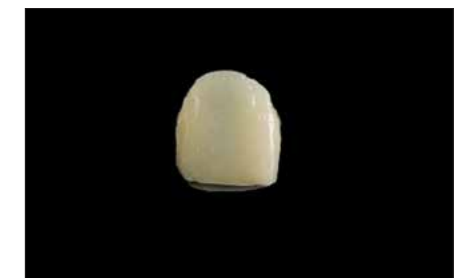

Fig. 6: Fished LuxaCrown.

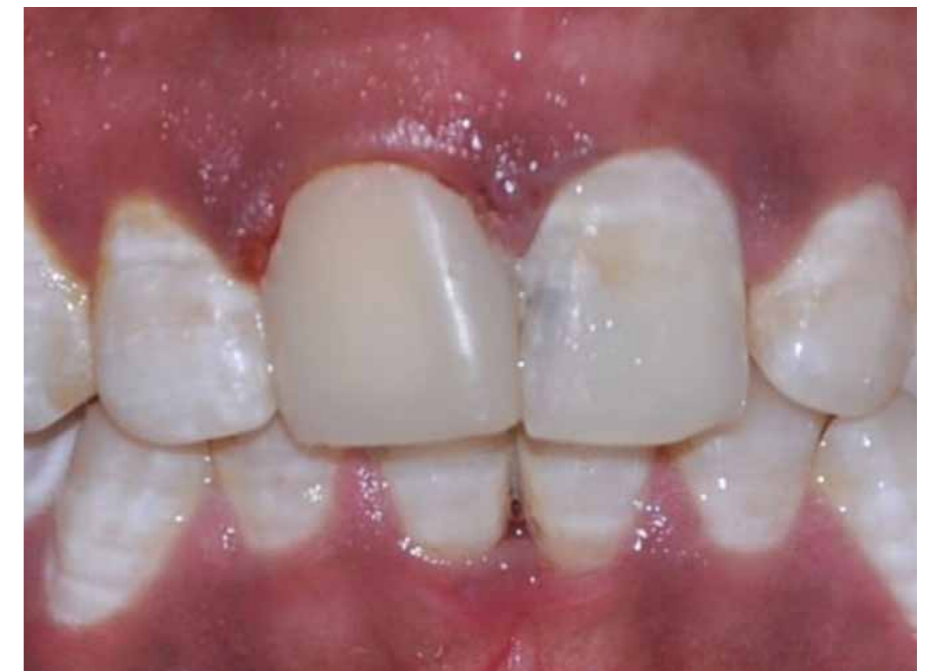

Fig. 7: Cemented LuxaCrown.

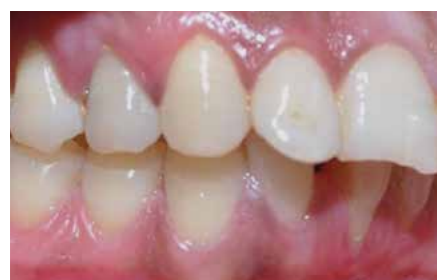

Fig. 1: Pre-operative situation.

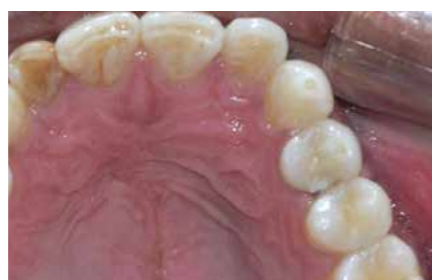

Fig. 2: Pre-operative situation.

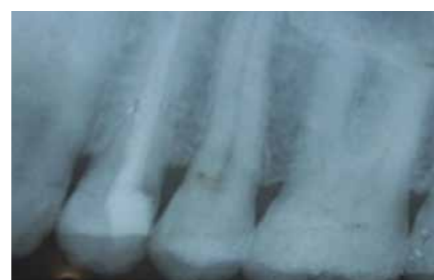

Fig. 3: RCT w.r.t 14.

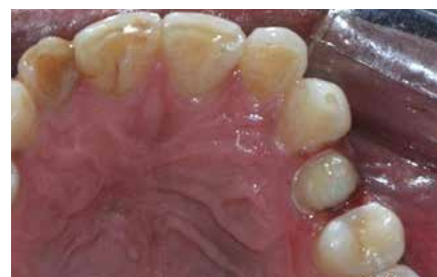

Fig. 4: Tooth preparation.

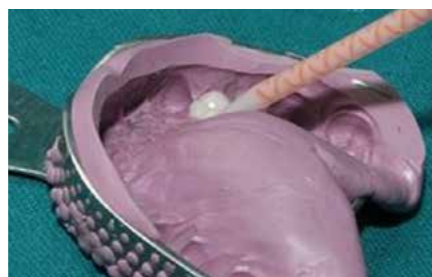

Fig. 5: Loading impression with LuxaCrown.

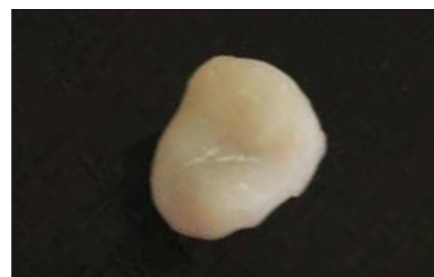

Fig. 6: Finished LuxaCrown.

CASE 3

In another case a 45 year old male patient who had recently been treated with endodontic therapy w.r.t maxillary right first premolar posterior tooth reported to the clinics with a requirement of crown on the RCT treated tooth (Figs. 1-3).

Patient was informed about the various restorative options and it was decided to deliver a long-term temporary crown using LuxaCrown (DMG, Germany). Informed consent was sought and a full mouth impression was taken using polysiloxane impression material and kept aside.

Crown preparation of the tooth in question was done following the standardized principles of tooth preparation (Fig. 4).

After shade selection the impression was loaded with LuxaCrown (Fig. 5).

This impression was then seated in the patient's mouth and crown was fabricated. The crown was then finished using composite finishing burs and pumice slurry followed by application of Luxatemp-Glaze and Bond (DMG, Germany) to achieve a smooth finish and lustre (Fig. 6).

The fabricated finished crown was then cemented onto the prepared tooth using Permacem 2.0 (DMG, Germany) (Figs. 8 and 9). A well-fitted crown with proper occlusion resulted in a good patient satisfaction.

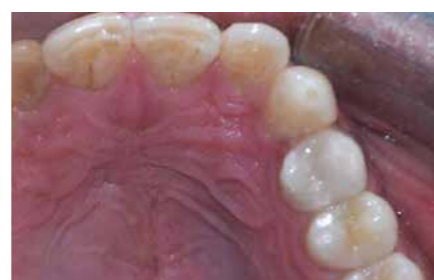

Fig. 8: Cemented LuxaCrown.

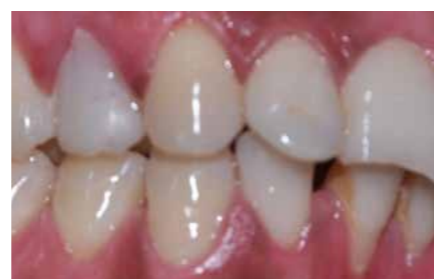

Fig. 9: Cemented LuxaCrown.

CASE 4

A 26 year old male patient reported to the department with the chief complaint of broken down upper front tooth (Fig. 1). The patient had a fall 3 years back when he was diagnosed with Ellis class III fracture with maxillary right lateral incisor. The patient had already undergone an RCT w.r.t 12 after the fall. The present concern of the patient was to get the esthetic rehabilitation of the tooth.

It was decided to restore the tooth using a full coronal restoration fabricated using LuxaCrown (DMG, Germany).

An initial elastomeric impression of the patient was taken and a cast was poured in dental stone. On this cast, a wax build up was done for 12 to simulate the tooth to its natural tooth anatomy – so that same can be used as an indirect technique to fabricate the crown. A fibre post was placed w.r.t 12 and core build up was done, followed by crown preparation for the same (Fig. 2).

An elastomeric impression was made on the cast. This elastomeric impression (putty index) was loaded with LuxaCrown and the loaded elastomeric material was placed into the patient's mouth. The crown thus obtained was finished with the help of composite finishing burs.

Pumicing and Luxatemp-Glaze & bond application was done to obtain a final finish of the crown. It was then cemented using PermaCem 2.0 (Fig. 3) and yielded excellent esthetics and great immediate patient satisfaction (Fig. 4).

CONCLUSION

The full coronal restorations fabricated using LuxaCrown demonstrated clinically good esthetics with excellent marginal adaptation. It can effectively be used for both anterior and posterior teeth and can be advocated as cost-effective long term temporaries or semi-permanent crowns.

CONTACT:

Prof. Dr. Neeraj Gugnani, MDS, MSc
DAV (C) Dental college Yamuna Nagar
135001, Haryana
India

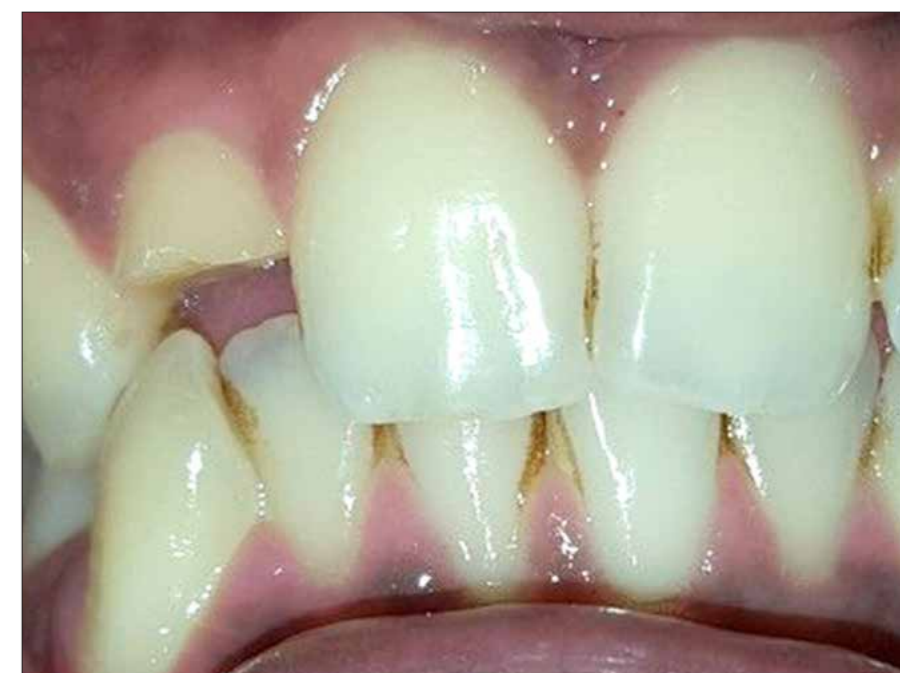

Fig. 1: Pre-operative situation.

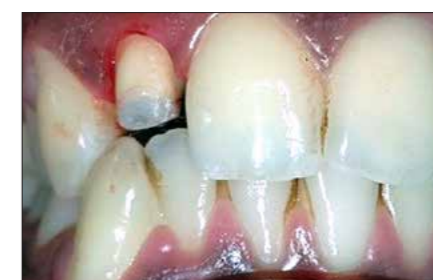

Fig. 2: Core build-up.

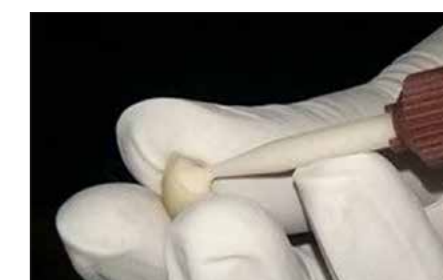

Fig. 3: Permanent cementation of LuxaCrown.

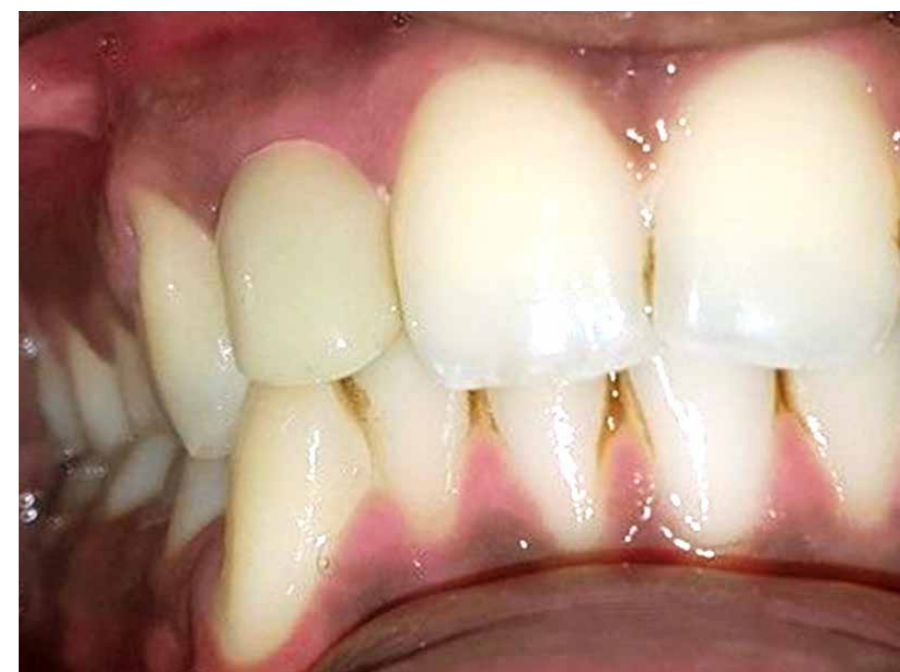

Fig. 4: Post-operative situation with LuxaCrown.

Restoring aesthetics and function with a reliable long-term restoration.

Application of a new semi-permanent material for exceptional clinical results.

Dr. Kleanthis Manolakis, DDS, Anthi Batziou, DDS, Greece

Clinicians often face great challenges dealing with extensive restorative clinical cases. Redefining aesthetics and function in failing dentitions is many times a challenging and time-consuming process. During the temporary restoration phase not only aesthetics and function need to be discussed with the patient and the restorative team, but also establishing endodontic and periodontic stability is of primary interest. During this temporary phase, which at times may last a prolonged period of time, the use of high performance temporary restorative materials can be beneficial. In the case presented below the use of a new supreme quality composite material designed to serve as a long-term quality semi-permanent restorative material will be discussed.

CASE PRESENTATION

The 35-year old female patient presents to our office with the wish to restore her upper and lower dentition. Both jaws were restored with fixed bridges many years ago. She experiences pain and discomfort and complains about recurrent infections in her lower jaw. She also feels uncomfortable with her dental aesthetics. Her primary concern is to restore her lower jaw first, then proceed with the upper jaw. An initial panoramic radiograph (Fig. 1) shows extensive restorations in both jaws. Only a few teeth are left in the lower jaw, presenting extensive bone loss, periapical infections and root fractures. All of her lower teeth are unfortunately unsalvageable. Additionally there is also an extensive crestal bone loss present at the posterior segments of her lower jaw. Luckily there is just enough bone present for the placement of four titanium implants in the interforaminal segment. The treatment of choice for

restoring her lower jaw is a short arch fixed implant retained composite veneered bridge. This solution restores her health issues, her function and aesthetics in a very favorable way.

A few months later the decision is taken to restore also the upper jaw. Her main concern is that the shape and color of her teeth are not pleasing (Fig. 2). Additionally, during the intraoral inspection, it is obvious that the restorative margins are insufficient (Fig. 3); several teeth present cervical carious lesions (Fig. 4).

An extensive wear pattern is obvious from the occlusal view. When designing a new restoration for this extensive case several issues need to be taken into account. Tooth shape, tooth color and establishing optimal restorative margins for maintaining periodontal health are factors of great importance that need to be taken care of.

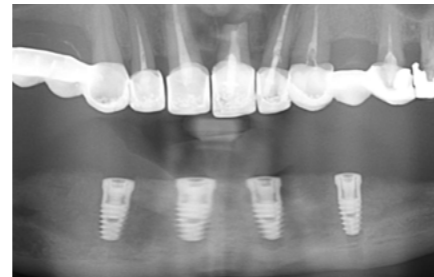


Fig 1: Initial panoramic radiograph.

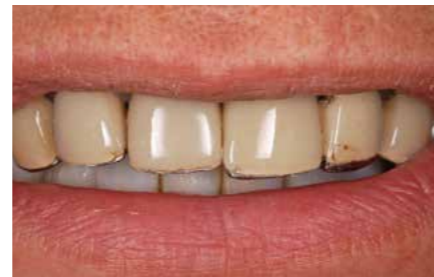

Fig. 2: Lack of harmony during smiling.

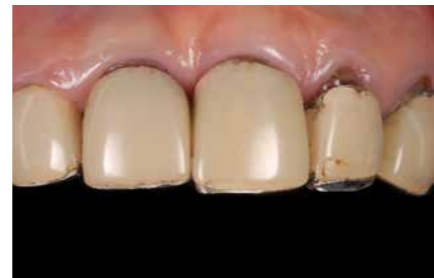

Fig. 3: Insufficient margins.

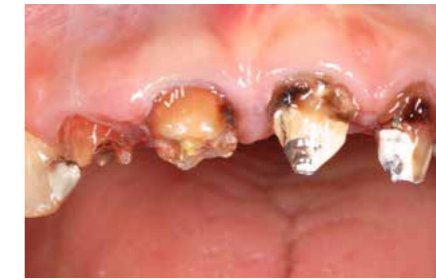

Fig. 4: Extensive destruction of hard tissue..

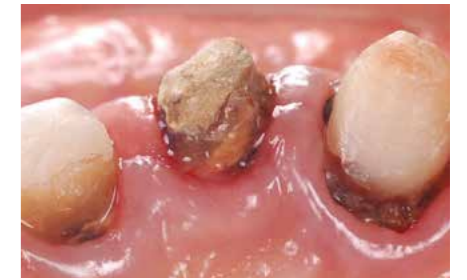


Fig. 5: Multiple extensive carious lesions..

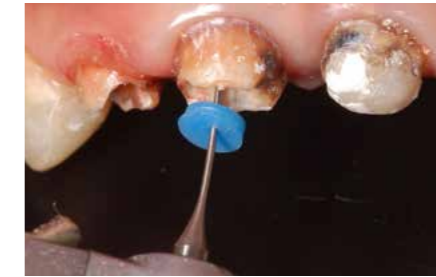

Fig. 6: Endodontic reentry.

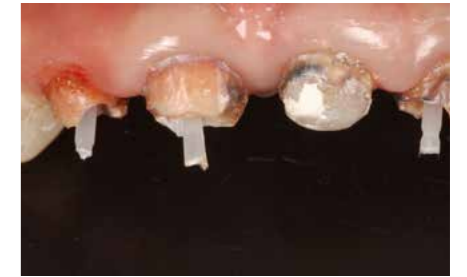


Fig. 7: Try-in of LuxaPost posts.

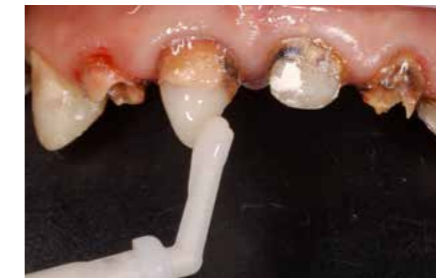

Fig. 8: Post cementation and core build-up with LuxaCore Z.

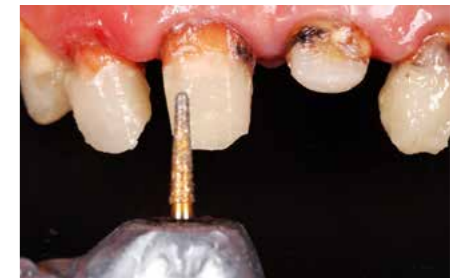

Fig. 9: Tooth preparation.

Upon removal of the upper existing restorations extensive loss of enamel and dentin are present, as expected.

Several teeth present carious lesions at their cervical region, buccally as well as palatally (Fig. 5). A positive issue is that she is not presenting extensive crestal bone loss around the existing upper teeth; her periodontal tissues are stable. A simple acrylic provisional restoration gives her a limited level of comfort and self-confidence during the initial restorative phase.

Complex cases presenting such an extensive loss of hard tissue and also involving extensive endodontic pretreatment always pose a flexible decision making process.

Every single tooth in the upper jaw is affected by extensive lack of hard tissue, coronal and marginal decay, as well as endodontic infection. Also the gingival margins need to be reestablished involving periodontal surgery to some extent, with or without crestal bone removal. Every single tooth needs to be assessed individually in terms of its prognosis. Usually it is extremely difficult to predict each tooth survival possibilities in a short-term basis; in these complex cases it is always advisable to run through a long-term temporary phase of several months up to even some years occasionally.

Respecting this long-term evaluation process the need for a high quality restoration is of paramount importance.

The first restorative step involves endodontic reentry in all already endodontically compromised treated teeth.

This step is performed with Gates reamers and hand files (Fig. 6). After the root canals are filled with sealant, the build up takes place. For this reason the glass-fiber reinforced tapered LuxaPost posts (Fig. 7) were adhesively cemented with the dual cure composite core build-up and post cementation material LuxaCore Z (Fig. 8).

LuxaCore Z presents high compressive strength and thus ensures exceptional stability under the crown. Additionally LuxaCore Z cuts like natural dentine, thus allowing for a very easy and smooth preparation (Fig. 9). At this time point also the

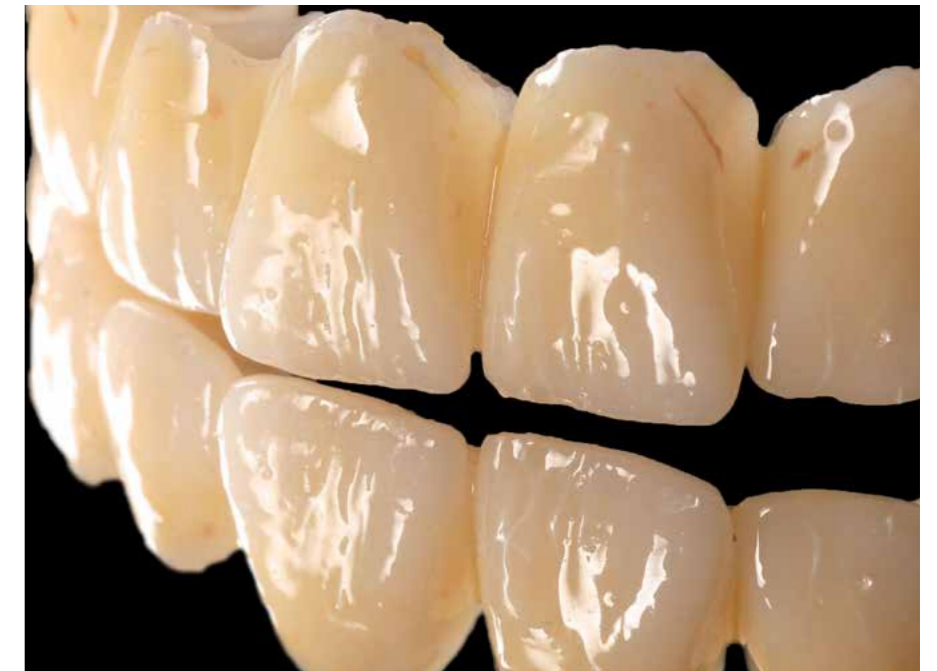

Fig. 10: Semi-permanent restoration with LuxaCrown.

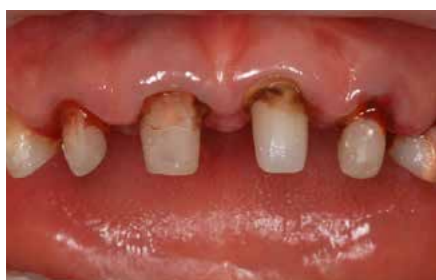

Fig. 11: Preparation for the adhesive cementation..

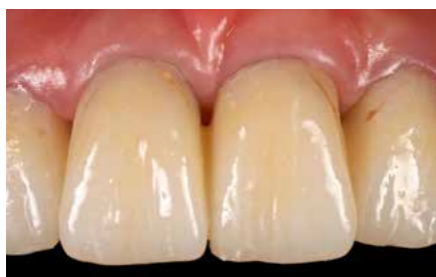

Fig. 12: Optimal marginal fit..

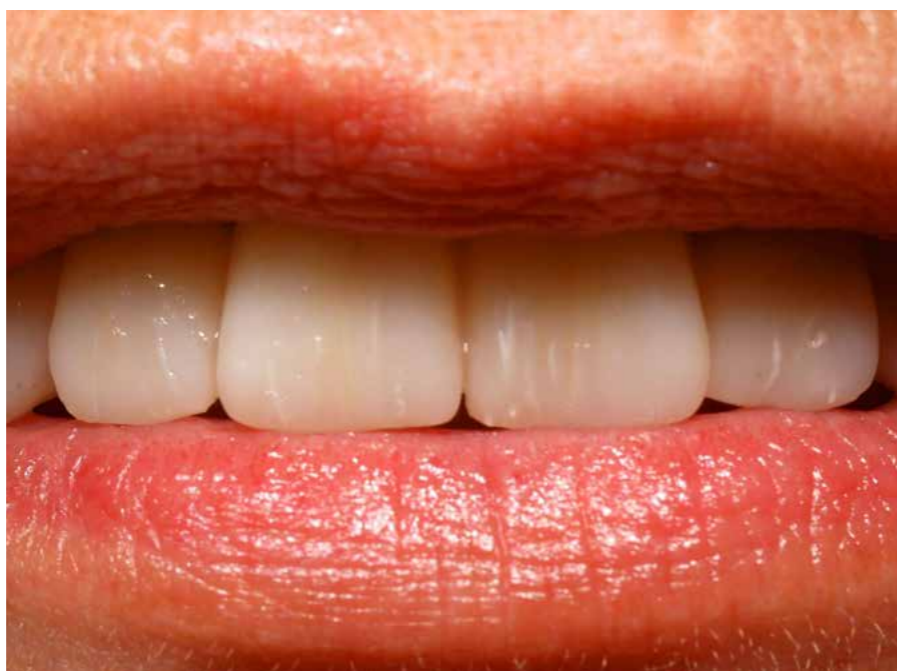

Fig. 13: Pleasing final outcome – oral harmony reestablished.

preparation margins are redefined, in order to ensure that no cervical decay lesions are left untreated in proximity to the margins. The step of soft tissue removal is initially performed under local anaesthesia with electrotomy; no osseous resection was performed yet.

After all preparations are completed and gingival retraction cord is placed, a precise VPS Honigum full arch impression is taken. Additionally a sectioned rigid bite registration is taken with O-Bite. Finally the existing provisional bridge is relined with Luxatemp.

In the lab a precise stone master cast is manufactured. All teeth are sectioned and the margins are trimmed.

The long term restoration has to follow these margins for the time needed until the treatment plan is finalized; several months will pass until individual tooth risk has been assessed and soft tissue has settled and matured around the new margins.

For the semi-permanent restoration a composite with optimal handling properties was chosen, LuxaCrown.

LuxaCrown presents optimal mechanical properties, but also an exceptional aesthetic outcome (Fig.10).

The restoration has no metal reinforcement, as there are no long spans between abutment teeth. At the time point of final cementation OptraGate is placed and all abutment teeth are cleaned properly (Fig. 11).

An adhesive cementation with dentin pretreatment and dual cure composite cement PermaCem 2.0 will be performed.

After adhesive cementation composite cement residues are removed carefully. The final aesthetic and functional clinical outcome is exceptional (Fig. 12). The lip support is optimal, the overall aesthetic appearance is very pleasing (Fig. 13).

SUMMARY

In extensive and challenging clinical cases where a trustworthy and effective long-term solution is needed, a new generation of semi-permanent material should be given priority.

It displays exceptional mechanical properties, ease of handling and optimal aesthetic results.

CONTACT

Dr. Kleanthis Manolakis, DDS
 Anthi Batziou, DDS
 95 Tsimiski Str.
 54622 Thessaloniki
 Greece

DMG

Chemisch-Pharmazeutische Fabrik GmbH

Elbgaustraße 248 22547 Hamburg Germany

Fon: +49. (0) 40. 84 006-0 Fax: +49. (0) 40. 84 006-222

info@dmg-dental.com www.dmg-dental.com

www.facebook.com/dmgdental

