

Sandwich technique for minimal invasive bonded porcelain veneers

Sillas Duarte, Jr*, DDS, MS, PhD; Eric Vilarreal, DDS Case Western Reserve University undergraduate student; Tomikazu Tada, RDT; MDC. Jin-Ho Phark, DDS, Dr. Med. Dent.

* Sillas Duarte Jr, DDS, MS, PhD Associate Professor,
Department of Comprehensive Care
Case School of Dental Medicine
Case Western Reserve University
10900 Euclid Avenue
Cleveland, Ohio 44106-4905
Phone: (216) 368-6737
Email: sillas.duarte@case.edu

Introduction

Restoring esthetically discolored, malformed, poorly restored, or broken-down teeth represents a challenge in routine dental practice.^{1, 2} Indirect porcelain veneers are the ideal restoration for intrinsically stained teeth.³ However, porcelain laminate veneers can be affected by the color of prepared abutment teeth.⁴ Minimal preparation associated with subopaquing the abutment teeth allows a progressive lightening of highly stained teeth to create natural shade depth in porcelain veneer procedures.^{2, 5, 6}

The clinical success of minimally invasive preparation for porcelain veneers depends on the high precision impression material/technique and skilled dental technician. Polyvinyl siloxane (PVS) has demonstrated the ability to copy the finest details of high demanding restorations.⁷ The impression technique also plays an important role in the esthetic rehabilitation procedure. The technique of choice for porcelain veneers is a one-step/double-mix impression using polyvinyl siloxane materials associated with a „double cord“ gingival displacement.⁸

The present clinical report describes an example of esthetic rehabilitation of anterior teeth using porcelain veneers together with one-step/double mix impression technique.

Clinical Case

A 22-years old patient with good oral health had a discolored grayish central incisor (21) and a color defective composite resin restoration on the other central incisor (11) (Fig. 1). The patient was seeking improvement of the anterior esthetics and the close of the small diastema between two central incisors.

Bonded porcelain veneers were suggested to correct the teeth shape and restore the discoloration as well as convey a pleasant esthetic appearance. An alginate impression was taken and poured in type IV synthetic dye to analyze the interocclusal relationship. An additive wax-up was used to establish the correct contour of the central incisors.⁹ A silicone matrix was made from the diagnostic wax-up and used as guide for the teeth preparation.¹⁰ The patient was not anesthetized to control the depth of preparation. Tooth 11 received a minimal preparation of 0.3 mm thickness, leaving the preparation entirely on the enamel. For tooth 21, a preparation depth of 0.5 mm was performed at the entire facial surface. The difference in preparation depth for each tooth was used to compensate for the gray discoloration. After the preparation, the tooth was acid-etched with 37% phosphoric acid gel for 15 seconds, washed and air-dried. A simplified total-etch dentin adhesive (TECO, Silvr Dose, DMG, Hamburg, Germany) was applied to tooth 21, and light cured for 20 seconds. Next, an A1 opaque composite colorant was used at the gingival third to mask the gray discoloration. The prepared teeth were then polished with rubber points and prepared for impression. A double cord technique was used for deflexion of the soft tissues. The large retraction cord was left in place for 5 minutes before impression (Fig. 2). After the initial

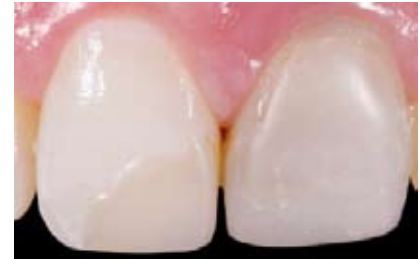

Fig. 1 Preoperative view of teeth 11 and 21 showing defective restorations

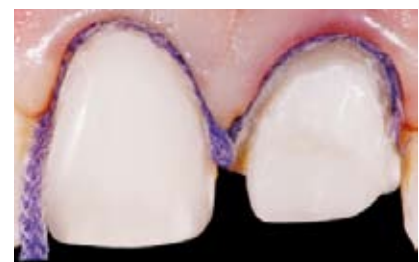

Fig. 2 Preparations ready for impression showing double cord retraction technique

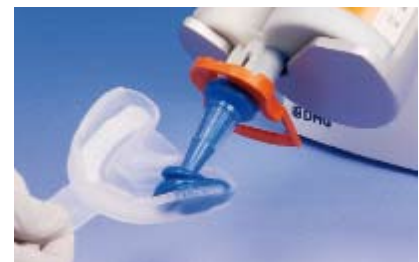

Fig. 3 Impression tray carefully and homogeneously filled with the Honigum-MixStar Putty

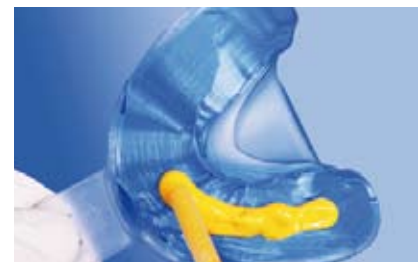

Fig. 4 Honigum-Light is applied over the Honigum-MixStar Putty

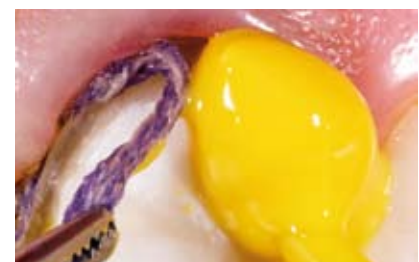

Fig. 5 Honigum-Light is applied at the same time the retraction cord was removed

preparation, the teeth were cleaned with water spray, and air-dried. A disposable impression tray was selected according to the patient arch size.

Minimal invasive preparations require a precise impression material and technique; otherwise, detailed areas would not be accurately duplicated. Thus, selection of a hydrophilic material such as PVS is imperative for meticulous reproduction of the preparations.⁷ In addition, the sandwich technique should be selected because of the high accuracy and quality of the obtained impression.^{8,11} Mechanical automixing of the impression materials is highly advocated, in order to obtain adequate consistency. Automixing of PVS materials has been shown to reduce or eliminate voids, prevent the risk of contamination, and improve PVS physical properties when compared to those of spatula-mixed materials.¹² An automix unit for impression materials (MixStar-eMotion, DMG) was loaded with Honigum-MixStar Putty (DMG) and a preconfigured program was used, per manufacturer's instructions. The impression tray was carefully and homogeneously filled with Honigum-MixStar Putty (Fig. 3). Note that each side of the tray was completely filled before extending to the other areas. Subsequently, Honigum-Light was also automixed and extruded directly over Honigum-MixStar Putty in the tray (Fig. 4). Honigum-Light must be applied not only in areas of the preparation but also to the total extension of the arch. This procedure allows a correct occlusal equilibration of the stone casts. In the meantime, the retraction cord was removed and Honigum-Light was applied simultaneously to the preparation (Fig. 5). The loaded tray was positioned into the mouth. After the material was completely set, the impression was removed and examined (Fig. 6). All the details of the minimal preparation were visible (Fig. 7). A close-up view of the impression revealed a fine and detailed reproduction of the preparation finishing line. In addition, the PVS high accuracy was observed in a cross-sectioned view of the impression (Fig. 8). Note the penetration of Honigum-Light within the gingival sulcus. Provisionals were fabricated for the prepared teeth and the patient was dismissed.

The impression was poured with a type IV synthetic die (Fig. 9). Two porcelain veneers were produced for teeth 11 and 21 with 0.3 mm and 0.5 mm thickness, respectively (Fig. 10).

The provisional restorations were removed and a porcelain veneer try-in performed. Try-in shaded glycerin pastes were used because of the high translucency of the porcelain veneers. A translucent shade was selected for tooth 11 and an A3 opaque composite was selected for tooth 21 to mask the discoloration. After patient and clinician final approval, the porcelain veneers were bonded to the teeth. The bonded restoration shows the adequate esthetic outcome (Fig. 11).

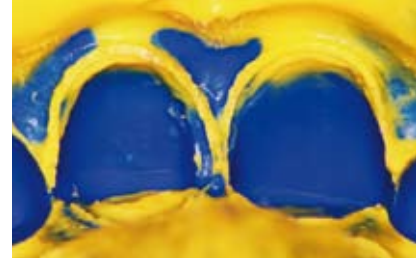


Fig. 6 View of the impression after setting



Fig. 7 Close-up view of the preparation




Fig. 8 Observe the PVS accuracy was observed in a cross-sectioned view of the impression

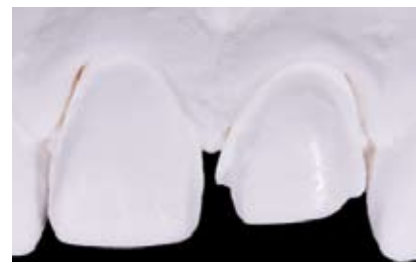

Fig. 9 Stone cast of the prepared teeth

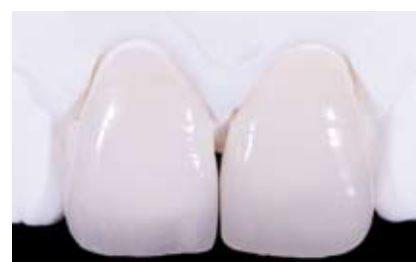

Fig. 10 Lingual view of the porcelain veneers

References

1. Christensen CJ. Veneering of teeth. State of the art. *Dent Clin North Am* 1985;29(2):373-91.
2. Ferrari M, Patroni S, Balleri P. Measurement of enamel thickness in relation to reduction for etched laminate veneers. *Int J Periodontics Restorative Dent* 1992;12(5):407-13.
3. Cutbirth ST. Indirect porcelain veneer technique for restoring intrinsically stained teeth. *J Esthet Dent* 1992;4(6):190-6.
4. Yamada K. Porcelain laminate veneers for discolored teeth using complementary colors. *Int J Prosthodont* 1993;6(3):242-7.
5. Javaheri D. Considerations for planning esthetic treatment with veneers involving no or minimal preparation. *J Am Dent Assoc* 2007;138(3):331-7.
6. Okuda WH. Using a modified subopaquing technique to treat highly discolored dentition. *J Am Dent Assoc* 2000;131(7):945-50.
7. Beier US, Grunert I, Kulmer S, Dumfahrt H. Quality of impressions using hydrophilic polyvinyl siloxane in a clinical study of 249 patients. *Int J Prosthodont* 2007;20(3):270-4.
8. Perakis N, Belser UC, Magne P. Final impressions: a review of material properties and description of a current technique. *Int J Periodontics Restorative Dent* 2004;24(2):109-17.
9. Magne P, Douglas WH. Additive contour of porcelain veneers: a key element in enamel preservation, adhesion, and esthetics for aging dentition. *J Adhes Dent* 1999;1(1):81-92.
10. Magne P, Belser UC. Novel porcelain laminate preparation approach driven by a diagnostic mock-up. *J Esthet Restor Dent* 2004;16(1):7-16; discussion 17-8.
11. Pant R, Juszczak AS, Clark RK, Radford DR. Long-term dimensional stability and reproduction of surface detail of four polyvinyl siloxane duplicating materials. *J Dent* 2008;36(6):456-61.
12. Keck SC. Automixing: a new concept in elastomeric impression material delivery systems. *J Prosthet Dent* 1985;54(4):479-83.

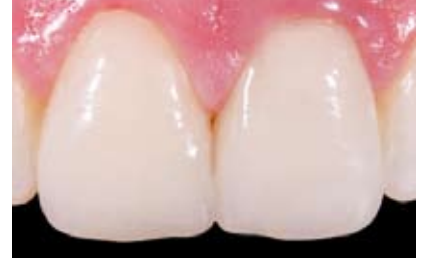

Fig. 11 Final outcome revealing a satisfactory esthetic appearance