



Post-endodontic restoration of a deeply decayed tooth – options and limitation

Michael Bruder, DDS with own practice, Hamburg

In some cases root canal treated teeth with extensive loss of coronal hard tissue require a post as additional supporting element for the build-up and definitive restoration. For quite some time now glass fiber enforced composite posts have become an established alternative to metal and ceramic posts [1]. Frequently, various different composites are required for setting the posts and for restoring the lost hard tissue portions. A complete system with matching components would be most welcome.

Such a system will be presented in the following article.

The long-term prognosis for a root canal treated tooth depends on the endodontic treatment as well as on the post-endodontic restoration [2].

The objectives for the restorative measures after filling the root canal are to restore the function, create a bacteria-proof closure, and contain the fracture risk.

The question whether or not the loss of pulp including the blood vessel system would cause a tooth to dry out and thus increase the risk of fracture was discussed for a long time. However, numerous studies showed no change of the hard tissue's physical properties after a vital extirpation and subsequent endodontic treatment. The fracture risk of an endodontically treated tooth is mainly due to the trepanation-based loss of the pulp cavity roof. The root canal and post bed preparations also contribute, though on a minor scale, to the reduction of the hard tissue and thus to weakening the tooth.

The indication for the restoration of endodontically treated teeth with posts has undergone a significant change in recent years [3]. While a restoration including a post build-up used to be considered a stringent indication in the past, today many dental professionals agree that rather the amount of remaining hard tissue is the decisive factor for a root post application (2).

More simply phrased, for front teeth and premolars an intraradicular cementation of the restoration is required if only two coronal dentine walls remain. If the remaining two dentine walls on molars are less than 3mm high and only a flat pulp cavity exists with insufficient retention surface for an adhesive restoration a root post is indicated as well [4].

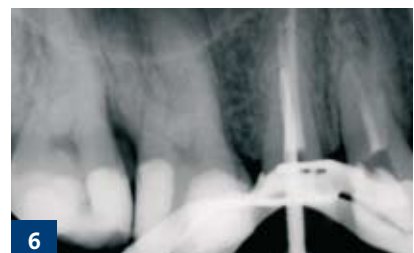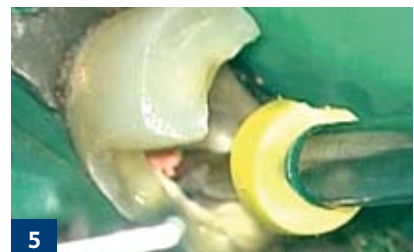
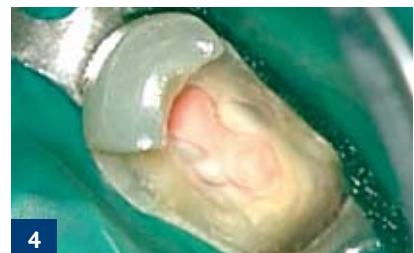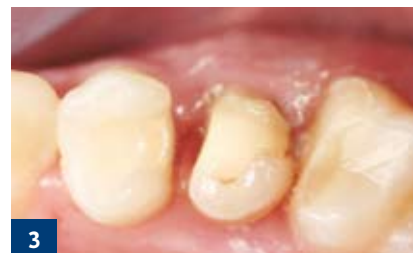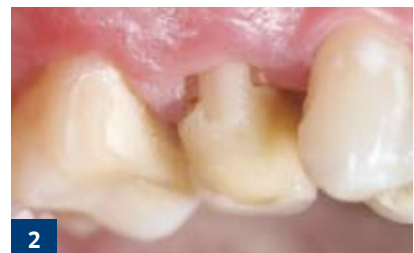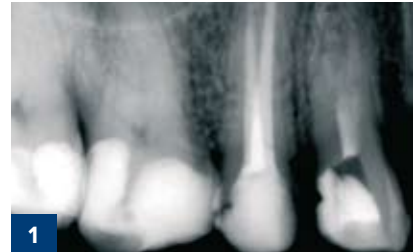As far as a bacteria-proof closure is concerned a post-endodontic restoration should be performed without delay. This requirement also takes into account the procedure for a planned post insertion. For one, temporary luting cements cannot sufficiently prevent a re-infection of the endodont through saliva, and secondly, temporarily cemented posts increase the risk of a longitudinal fracture. Glass fiber enforced composites make it possible to begin reconstruction immediately following the root canal filling, thus fulfilling the above-mentioned requirement.

Material

Three post sizes with diameters of 1.25 mm, 1.375 mm, and 1.5 mm in tapered form are available. For each size a corresponding post drill is included in the set. Due to their cutting performance pre-drilling is not necessary.

The posts are silanized with a two-component system consisting of an adhesive silane and activator to create a chemical bond between the glass fibers and the composite's resin matrix.

LuxaBond-Total Etch is a fourth generation adhesive system consisting of a prebond, an adhesive to be mixed, and corresponding endo brushes specifically designed for root canal applications.





For the post cementation and filling of the coronal cavity LuxaCore Z-Dual, a dual-curing, fluid, and highly pressure resistant composite is used.

Case report

The following case report is a step-by-step description of a post-endodontic restoration of a deeply decayed upper jaw premolar with an adhesively cemented glass fiber post and core build-up.

A 22 year old patient visited our practice in search of treatment.

The patient's general medical health history was normal. The dental anamnesis showed a fracture of the clinical crown of the endodontically treated tooth no. 15 (initial x-ray, figure 1). An emergency medical service had previously treated the premolar with a temporary restorative filling (initial situation, figures 2 and 3).

The inspection of the tooth's hard tissue after removal of the filling showed a remaining palatal dentine wall so that a post insertion could be indicated.

A rubber dam was applied in order to prevent further contamination of the endodont and to not impede the adhesive reconstruction of the crown through saliva penetration (figure 4).

Based on the buccal defect situation the respective canal for the insertion of the post was chosen (LuxaPost, DMG). The canal's cross-section determined the selection of the 1.5 mm post diameter.

A drill with length marker matching the post diameter was used to prepare the post canal (figure 5). The preparation depth depended on the working length of the root canal treatment. The objective was to leave 4 mm of the apical root canal filling as a sealed closure. An x-ray with post drill was used a) to control the targeted canal depth, and b) to monitor the correct preparation direction (figure 6).

The post bed was first rinsed with a 17% EDTA solution to remove the smear layer and then disinfected with a 5.25% NaOCl solution. After drying the well, the post was seated and checked using a marker and foil pen (figure 7).

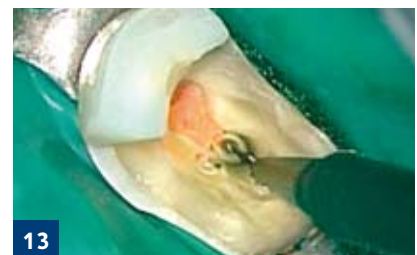
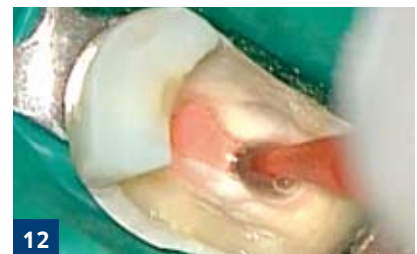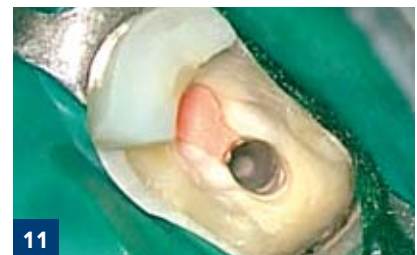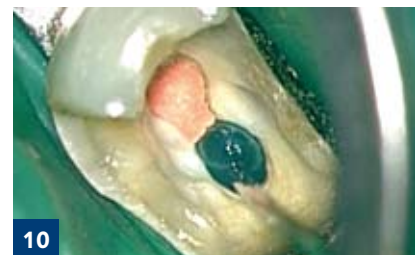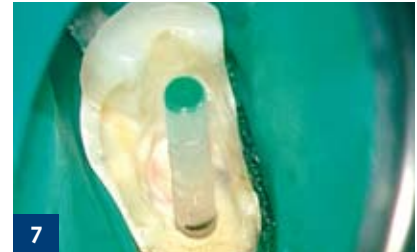With artery forceps the post was fixated at the top, cleaned with alcohol, and dried with air (figure 8). The silanization concluded the preparation of the post for insertion (figure 9).

In the next step the post bed and the coronal cavity were conditioned with 37% phosphoric acid. After etching the enamel for 20-60 seconds and the dentine for 15 seconds, both areas were rinsed for the same amount of time (figure 10).

After careful drying with moisture-free compressed air (figure 11), the prebond was applied to all dentine areas for 15 seconds using an endo brush (figure 12) and gently blown off.

Subsequently, the components A and B of the bonding system were mixed in a 1:1 ratio for approx. 5 seconds, worked into all dentine areas for 20 seconds (figure 13), and also gently blown off. Following both steps, the post well was additionally dried with paper syringes (figure 14). Light-curing is not necessary for this chemically curing adhesive system.

For the post cementation the canal was completely filled with LuxaCore Z-Dual, and with gentle rotating motions the post was moved to the targeted position. This procedure prevents bubble formation to a great extent and promotes an optimal bond of the components involved: post, composite, and canal wall dentine. A 40 second light polymerization accelerates the curing process. (figure 14)



For information only.





For the reconstruction of the coronal portion LuxaCore Z-Dual was used as well and light-cured as described above (figure 15).

After the so-called ferrule preparation was completed (figure 16 and 17) a provisional was made and cemented in using a temporary adhesive.

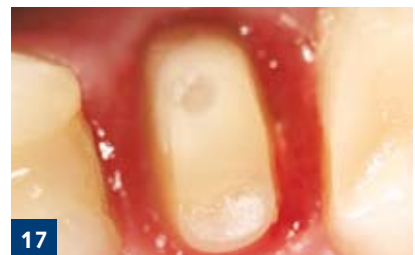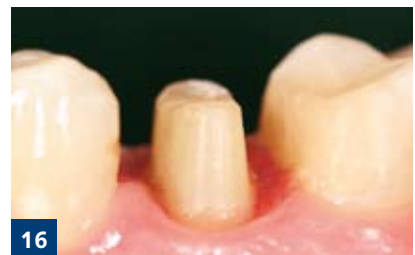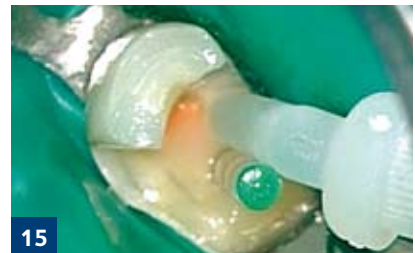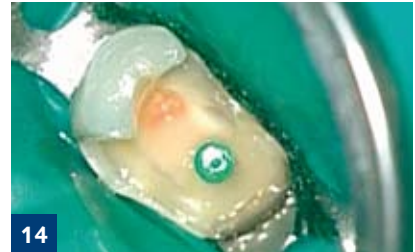Summary

In cases where the clinical crown is extensively destroyed the retention of an adhesive restoration is limited and a root post may be necessary in order to improve this retention. Glass fiber enforced composite posts are especially well-suited due to their prompt and direct application, their dentine-like material properties, and their optical advantages. With regard to their biomechanical characteristics core build-up materials are primarily designed to replace lost coronal dentine. As to its mechanical and polishing properties LuxaCore Z-Dual is very dentine-like [5]. However, long-term clinical studies need to show whether or not the material properties of the posts or the bond between the dentine, composite, and post may have adverse effects under permanent load.

Besides the composite root post, the advantage of this DMG system is to have all the materials necessary for a post-endodontic treatment available from one source. Therefore, this system can be rated as practical and reliable.

Literature

1. Grandini S, Goracci C, Tay FR, Grandini R, Ferrari M. Clinical evaluation of the use of fiber posts and direct resin restorations for endodontically treated teeth. *Int J Prosthodont*. 2005; 18 (5): 399-404
2. Fernandes AS, Dessai GS. Factors affecting the fracture resistance of post-core reconstructed teeth: a review. *Int J Prosthodont* 2001. 14 (4): 355-63
3. Schwartz RS, Robbins JW. Post placement and restoration of endodontically treated teeth: a literature review. *J Endod*. 2004; 30 (5): 289-301
4. Dietschi, Duc O, Krejci I, Sadan A. Biomechanical considerations for the restoration of endodontically treated teeth: a systematic review of the literature – Part 1: Composition and micro- and macrostructure alterations. *Quintessence Int*. 2007; 38 (9): 733-49
5. Cachovan G, Lasson I, Effenberger S, Schiffner U. In-vitro Vergleich der Beschleifbarkeit verschiedener Stumpfaufbaumaterialien (in-vitro comparison of the polishability of different core build-up materials). *Dtsch Zahnartzl Z* 2007;62 (Suppl 2007):D10.



Please address correspondence to
Michael Bruder
Otto-Ernst-Str. 3
22605 Hamburg
Germany

